

## Migration of a Kirschner Wire Lead to Brachial Artery Injury after Fixation for Proximal Humerus Fracture A Case Report

### Abstract

K-wires are generally used in orthopedic fracture surgery. Pinning with metal wires is a reasonable option for proximal humeral fractures treatment. One 91-year-old man received multiple K-wire fixation for left proximal humeral fractures. Later in postoperative follow-up at the outpatient department, he illustrated symptoms of tenderness, swelling, coin-sized bullae formation and ecchymosis over left axillary region. K-wire migration was noted, which led to brachial artery injury with traumatic pseudoaneurysm formation. The patient underwent emergent surgery where previously placed K-pins were removed and then received revascularization surgery afterward. Functional shoulder brace was adopted for his postoperative immobilization of left shoulder and fracture site bony union was noted a year later. He led independent activity of daily life as previously before the accident.

Previous documents had reported potentially dramatic complications related to wires migration and most of them were intra-thoracic migration cases. We present the uncommon case of brachial artery injury with traumatic pseudoaneurysm. While it may not be as detrimental injury as intra-thoracic migration of K-pins, brachial artery penetration could lead to more undetected clinical symptoms and result in irreversible damage. Orthopedic surgeons should consider related risks when using K-wire fixation over proximal humerus, especially in cases of elder patients with possible low compliance to immobilization and low bone quality. Most important of all, doctors must alert patients about the importance of returning for follow-up evaluation postoperatively, and for the removal of K-wires.

Received: 4 months before printing; Accepted: 20 days before printing

Chao-Jui Chang, MD<sup>1</sup>, Chih-Kai Hong, MD<sup>1</sup>, Chang-Han Chuang, MD<sup>2</sup>, Pei-Yuan Lee, MD, PhD<sup>2</sup>,  
Wei-Ren Su, MD, MSc<sup>1</sup>

<sup>1</sup>Department of Orthopaedics, National Cheng Kung University Hospital, College of Medicine, National Cheng Kung University, Tainan, Taiwan

<sup>2</sup>Department of Orthopaedic Surgery, Show Chwan Memorial Hospital, Changhua, Taiwan

#### Correspondence:

Chang-Han Chuang, MD  
Department of Orthopaedic Surgery, Show Chwan Memorial Hospital, Changhua, Taiwan  
542, SEC 1 CHUNG-SHAN RD., CHANGHUA, TAIWAN 500, R.O.C.  
E-mail: skyman889@gmail.com

### Introduction

the incidence is increasing due to population ageing and osteoporosis<sup>(1)</sup>. In stable and minimally displaced fractures, nonoperative management could lead to good result. Surgical intervention is necessary for the treatment of unstable and displaced fractures<sup>(2)</sup>.

Kirschner wires (K-wires), which can generally be placed percutaneously in the peripheral extremities and provide inexpensive simple fixation, were widely used in orthopedic fracture surgery. Pinning with metal wires is a reasonable option for proximal humeral fractures treatment, and the loosening with migration of such instrument from this site is rather rare.

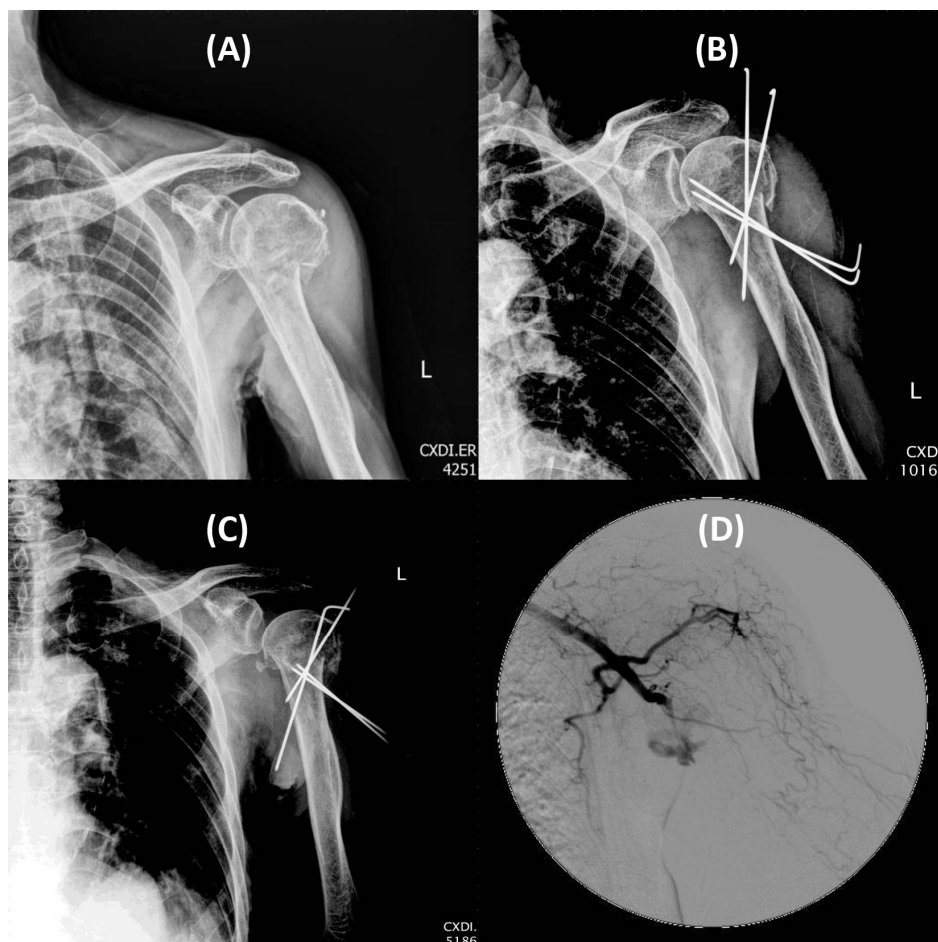
We present the case of K-wire migration with vascular injury post surgery for the treatment of proximal humeral fracture. To the best of our knowledge, brachial artery injury with traumatic pseudoaneurysm formation following the K-wire migration is uncommon, and the patient in this article represents the first such case described in the literature. The patient was well informed that data concerning the case would be submitted for publication, and he provided consent. Distinguished increase in the number of reports about the complications of migration of pins into vital organ and cavities had been noticed and this prompted us to propose the recommendations regarding the use of wires and pins around the shoulder girdle.

## Case Report

The patient was a 91-year-old man with underlying disease of hypertension, who lead an independent activity of daily life before the accident. He sustained a traffic accident with left shoulder contusion injury and was transferred to our level-I trauma center emergency department immediately after the accident. Traditional X-ray series revealed left proximal humeral fracture. According to Arbeitsgemeinschaft für Osteosynthesefragen (AO) classification, the fracture type was

11B1.1, but with Neer classification it was a three-part fracture (Figure 1A).

The day after the injury, the fracture was treated by close reduction-internal fixation (CRIF) with two retrograde and two anterograde K-wires (Figure 1B). The first two wires were retrograde inserted over the deltoid "V" level, while other two wires were anterograde percutaneously introduced to fix the great tuberosity and humeral head. The patient wore a shoulder sling for three weeks after the surgery and started standard rehabilitation program with passive range of motion protocol.



According to AO classification, the fracture type was 11B1.1, but with Neer classification it was a three-part fracture. (Figure 1A).

The fracture was treated by close reduction-internal fixation (CRIF) with two retrograde and two anterograde K-wires. (Figure 1B).

Radiography of left shoulder revealed downward migration of one anterograde and two retrograde K-pins (Figure 1C).

Left upper limb angiography showed brachial artery penetration by migrated K-pin with traumatic pseudoaneurysm formation. (Figure 1D).

At clinical follow-up after two weeks of surgery, the patient appeared clinically and radiographically stable. However, during four weeks postoperatively follow-up at the outpatient department, he illustrated symptoms of tenderness, swelling, coin-sized bullae formation with ecchymosis over left axillary region and there was no any abnormal discovery over the right side of upper extremity.

Physical examination manifested intact distal vascular circulation but with numbness sensation over all distal finger tips of left hand. Radiography of left shoulder was arranged for the patient, which revealed downward migration of one anterograde K-pins (Figure 1C). Left upper limb angiography was immediately performed and the result showed brachial artery penetration by migrated K-pin with traumatic pseudoaneurysm formation (Figure 1D). The patient underwent emergent surgery where all four previously placed K-pins were removed. He was then taken over by cardiovascular surgeon and received revascularization surgery. Functional shoulder brace was adopted for his postoperative immobilization of left shoulder and there was no other revascularization-related complications after the surgery. Fracture site bony union was noted three months later and the patient had normal function and sensation in the affected limb and hand, with independent activity of daily life as previously.

## Discussion

K-wires are generally used in orthopedic fracture surgery, not only are they inexpensive for simple fixation, it can also be placed percutaneously without complication in the peripheral extremities.

The first report about migration of K-pins into vital organ was discovered by Mazet et al. In 1943, he described the migration from shoulder region into thoracic cavity<sup>(3)</sup>. The migration of pins after operations whilst used

as minimal invasive fixation for fractures, dislocations and associated complications are well known nowadays. In spite of infrequent occurrence, the literature has reported potentially fatal and dramatic complications related to wires migration. One review article conducted by Lyons et al. reported that 20% (8/39) of intra-thoracic migration cases result from perforation of great vessels or via lethal heart<sup>(4)</sup>.

There are several contributing factors that can potentially affect the wire stability; in other studies hypothesis has been made as to possible reasoning made of partial bony reabsorption, gravitational pulling force, shoulder muscle strain, secondary fragment displacement, poor bone mineral density, inadequate wire positioning and the great freedom of shoulder movements<sup>(3, 5, 6)</sup>.

In the aforementioned statement, pins must be used with the utmost caution, especially in the fixation of proximal humerus. Patients must be closely monitored clinically and radiographically, while surgeons must be aware of possible detrimental complications.

In spite of the depressing complication of this case, there were several issues worth learning from the mistake. After careful consideration, we provided some suggestions for the prevention of associated disaster.

First, radiographs should be immediately obtained intraoperatively or postoperatively to document the location of the K-wires, stability should be checked through dynamic maneuvers.

Second, wires should be terminally threaded and bent over the free end to prevent further migration (keep in mind that regardless of bent or threaded, all types of wires have been reported to migrate)<sup>(4)</sup>.

Third, for tuberosity fixation, the use of a cannulated screw might be considered.

Fourth, regular radiographic and clinical follow-up is needed for patients with K-wire fixation; any migrated wires must be removed immediately despite the lack of symptoms and

difficulty in removal of the pin to prevent catastrophic complications.

Pseudoaneurysms, most of which are the result of penetrating injuries, could result in disastrous complications of extremities and even life<sup>(7)</sup>. Nerve injury and hemorrhage of distal limbs were not uncommon, amputation or loss of limb function can happen in thromboembolic cases<sup>(8-10)</sup>. Kemp et al. had described a case of pseudoaneurysms of the brachial artery who presented with an upper arm swelling, hand numbness and weakness that had developed following a humeral fracture. No residual neurological symptoms was noted after the surgical repair of the pseudoaneurysm<sup>(11)</sup>. In our case, there was near normal function and sensation in the affected limb after the revascularization surgery.

Back to this patient, multiple smooth K-wires were applied for fracture fixation of proximal humerus, and there was downward migration of K-wires (one anterograde and two retrograde K-wires). Fixation of fracture fragment had been ensured with the guidance of intraoperative fluoroscope during placement of each K-pin. Wires were bent at the end so that they could be maintained

above the skin. The patient's arm was immobilized in a sling for three weeks after the surgery. K-pin migration occur after initiating rehabilitation program with passive range of motion exercise. Even ensuring of secure fracture fixation and bending end of K-wires were executed during the surgery, K-wires migration still happened. The patient had been closely monitored clinically and radiographically after the surgery, so the k-pin migration could be detected during his postoperative follow-up.

## Conclusions

Orthopedic surgeons should consider related risks when using K-wire fixation over proximal humerus, especially in cases of elder patients with possible low compliance to immobilization and low bone quality. Patient-reported symptomatology is not always reliable, and radiographic evaluation is necessary. Most important of all, doctors must alert patients about the importance of returning for follow-up evaluation postoperatively, and for the removal of K-wires.

## References

1. Roux A, Decroocq L, El Batti S, Bonneville N, Moineau G, Trojani C, et al. Epidemiology of proximal humerus fractures managed in a trauma center. *Orthop Traumatol Surg Res.* 2012;98:715-9.
2. Zyto K, Ahrengart L, Sperber A, Tornkvist H. Treatment of displaced proximal humeral fractures in elderly patients. *J Bone Joint Surg Br.* 1997;79:412-7.
3. Mazet RJ. Migration of a kirschner wire from the shoulder region into the lung: Report of two cases. *JBJS.* 1943;25:477-83.
4. Lyons FA, Rockwood CA, Jr. Migration of pins used in operations on the shoulder. *J Bone Joint Surg Am.* 1990;72:1262-7.
5. Glauser F, Kremens V. Unusual sequela following pinning of medial clavicular fracture. *Am J Roentgenol Radium Ther Nucl Med.* 1956;76:1066-9.
6. Tristan TA, Daughtridge TG. Migration of a metallic pin from the humerus into the lung. *N Engl J Med.* 1964;270:987-9.
7. Johnston KW, Rutherford RB, Tilson MD, Shah DM,

- Hollier L, Stanley JC. Suggested standards for reporting on arterial aneurysms. Subcommittee on Reporting Standards for Arterial Aneurysms, Ad Hoc Committee on Reporting Standards, Society for Vascular Surgery and North American Chapter, International Society for Cardiovascular Surgery. *J Vasc Surg.* 1991;13:452-8.
8. Yetkin U, Gurbuz A. Post-traumatic pseudoaneurysm of the brachial artery and its surgical treatment. *Tex Heart Inst J.* 2003;30:293-7.
9. Moran D, Roche-Nagle G, Ryan R, Brophy D, Quinlan W, Barry M. Pseudoaneurysm of the brachial artery following humeral fracture. *Vasc Endovascular Surg.* 2008;42:65-8.
10. Kaczynski J, Wilczynska M, Fligelstone L. Flail upper limb due to delayed presentation of a traumatic brachial artery pseudoaneurysm. *BMJ Case Rep.* 2013;2013.
11. Kemp K, Radwan R, Shingler G, Davies C. Brachial artery pseudoaneurysm. *BMJ Case Rep.* 2014;2014.