

Femoral head reduction osteotomy for the sequela of traumatic hip dislocation in a six-year-old with the aid of 3D-printed models (A case Report)

Abstract

Traumatic dislocation of the hip is rare in children. Complications occur in cases with associated injuries and delayed treatment. Treatment options are limited in case of avascular necrosis. We report a case of 6 year old girl who presented with stiffness and deformity of left hip with increased lumbar lordosis and inability to walk due to a post traumatic AVN that happened after a traumatic hip dislocation at the age of 18 months. She successfully underwent head reduction osteotomy, utilizing pre-op 3D-printed models. The procedure was successful in terms of correcting her deformities, relieving pain and her ability to ambulate after 3 years of follow up. This case suggests that femoral head reduction osteotomy, with minimal modifications, can be performed in children as young as 6-years old. 3D-modeling is a great addition to the tools a surgeon can use, in the preoperative planning of difficult osteotomies, as well as education of the residents and fellows.

Keywords: Femur Head Necrosis «Avascular Necrosis of Bone» Hip dislocation, 3D printing, Osteotomy

Level of Evidence: Therapeutic Level V – Case report

Funding: No funding was received for this study.

Running head: Head reduction osteotomy in a 6-year old

Received: 5 months before printing; Accepted: 2 Months before printing

This investigation was performed at the Joint Reconstruction Research Center, Tehran University of Medical Sciences, Tehran, Iran

Soroush Baghdadi, MD* ; Taghi Baghdadi, MD**

* Joint Reconstruction Research Center, Department of Orthopedics, Tehran University of Medical Sciences, Tehran, Iran.

** The Children's Hospital of Philadelphia, Division of Orthopaedics, Philadelphia, PA.

*Corresponding author, requests for reprints: Taghi Baghdadi, M.D., Joint Reconstruction Research Center, Imam Khomeini Hospital, Keshavarz Blvd, Tehran, Iran 1419733141. Tel: 98-21-66581586, Fax: 98-21-61192767, Email: taghibaghdadi@hotmail.com
ORCID iD: 0000-0002-3015-3767

Introduction

Case History

A Traumatic hip dislocation is rare in children. Both low and high-energy mechanisms have been described⁽¹⁾. The periarticular structures are more flexible in children, and therefore, dislocations can occur in the absence of fractures, which is rare in adults. Acetabular and femoral head fractures do occur in some cases, which influences the treatment and prognosis drastically. Predictors of outcome include the presence of associated injuries, time to reduction, and mechanism of injury⁽²⁾.

Avascular necrosis (AVN) is the most frequent serious complication of traumatic hip dislocation, reported in 3-15% of cases⁽³⁾. Time to reduction has been a significant predictor of the development of AVN in multiple studies. Poor outcomes and early degenerative changes are to be expected as the consequence of traumatic femoral head AVN^(2, 3). In younger children, treatment options are limited, and hip fusion is inevitable in severely degenerated joints. However, hip fusion significantly limits the child's movements and vitality and is also not an acceptable treatment in some cultures. .

Hip preservation surgery, including femoral head reduction osteotomy, has been successful in delaying or mitigating the need for early joint replacements in multiple hip disorders. Femoral head reduction osteotomy was introduced by Ganz et al. in 2011, with the goal of treating coxa magna as a sequela of Legg-Calve-Perthes disease⁽⁴⁾. This procedure is an attempt to reshape the femoral head and provide a circular head within a congruous acetabulum. Further reports have shown that although technically challenging, this procedure is successful in alleviating pain and deformity if patients are carefully selected⁽⁵⁾. However, these procedures are typically performed in adolescents and young adults, and as such, the lower age limit for attempting such procedures and the technical issues in the younger child have not been described. We hereby present the case of a six-year-old patient with severe head deformity and AVN that underwent a femoral head reduction osteotomy. 3D-printed modeling was used to guide the osteotomy. We will also discuss the technical challenges of performing this procedure in younger children.

Case Report : A 6-year-old girl was visited at a tertiary referral pediatric

orthopedics clinic for a second opinion. She was unable to walk for the last 3 months. At the age of 18 months, she sustained a traumatic left hip dislocation following a car rollover accident. An anterior open reduction was performed 48 hours later, and the patient was discharged with a spica cast for two months. She walked painless with a minimal limp for the next year. After the age of 3, lumbar lordosis, limp, and the pain began to limit her activities. At the age of 5, a trial of non-weight bearing and skin traction at home led to the improvement of symptoms for only six months. At the time of referral, she was unable to walk more than a few steps and had to use assistive devices for longer ambulation. On physical examination, lumbar hyperlordosis was evident. Hip flexion contracture of 60° was present, with flexion up to 90°, no rotation and abduction, and 20° adduction. The neurovascular examination was normal. Radiographs showed a grossly deformed femoral head, which had an inferior flange, acetabular changes, and signs of early degeneration of the joint. A CT-scan and MRI were requested [Figure 1].

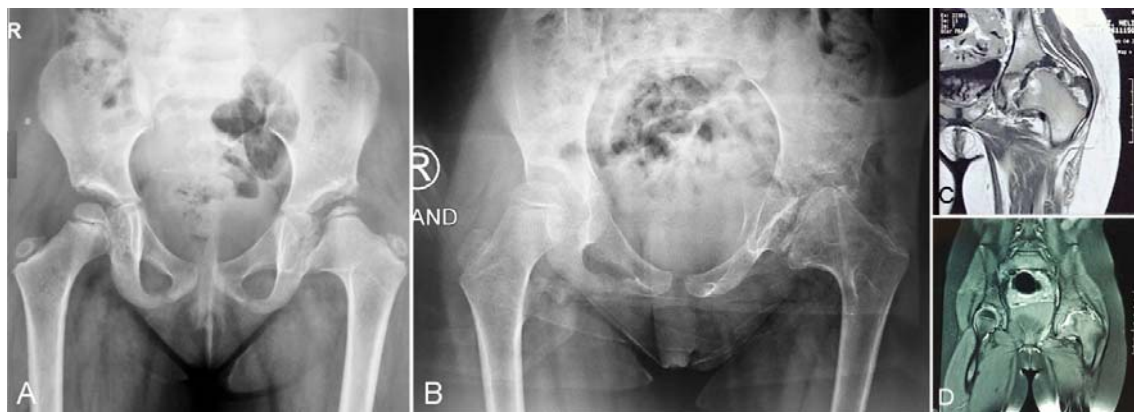


Figure 1 Preoperative imaging. Standing pelvic radiographs at the age of 3 (A) and at the time of referral (B). Femoral head deformity, and progressive acetabular changes are evident. T1-weighted (A) and T2-weighted (B) M.R. images showing an inferior protrusion in the femoral head, diffuse signal changes, and early degeneration in the acetabulum.

A diagnosis of post-traumatic AVN was made. Treatment options were limited due to her age, and hip fusion was suggested, which the family adamantly refused. With some viable cartilage visible on MRI, surgical dislocation of the hip and a femoral head reduction osteotomy was suggested. After considering the advantages and drawbacks of such a procedure in a 6-year-old, the parents

agreed to follow this path. A 3D-printed model of the pelvis and proximal femurs were made to allow precise preoperative planning. As evident in [Figure 2], the femoral head was large, with an inferior spike. The preoperative planning was done on the model, and the size and trajectory of the cuts were recorded to be replicated at the time of surgery.

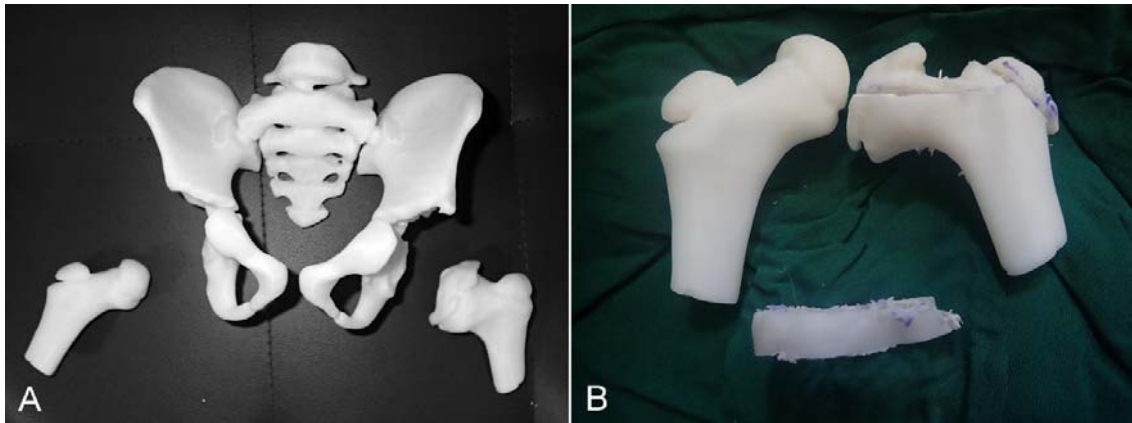


Figure 2 3D modeling. 3D-printed models of the pelvis and proximal femura, clearly showing the deformity and changes in the femoral head (A). Greater trochanteric osteotomy and femoral head reduction osteotomy were simulated on the models to achieve a spherical femoral head (B).

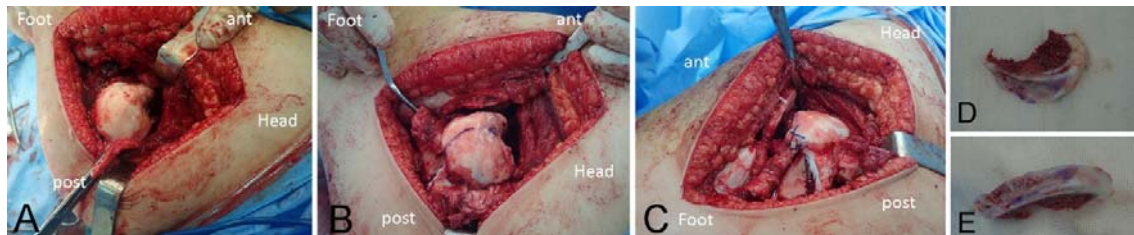


Figure 3 Intraoperative findings. A deformed femoral head (A), is marked for head reduction osteotomy based on preoperative planning (B). Headless screws and absorbable sutures were used for fixation (C). The excised fragment has clear signs of necrosis and degeneration (D, E).

The patient was operated in the lateral position, with a straight lateral incision, according to the Ganz technique⁽⁶⁾. After splitting the gluteus maximus muscle, the posterior femoral neck was dissected to locate the piriformis tendon. It was noted that the external rotators are not in their normal location, and they were horizontal, rather than oblique. The trochanteric osteotomy was performed while keeping a safe distance from the

piriformis, and the piriformis-gluteus minimus interval was then developed to access the capsule, which was thick and scarred. There was no ligamentum teres, and the dislocation was easy. The deformed femoral head was examined, and the osteotomy cuts were done exactly as was planned on the 3D-printed models, after developing an extended retinacular flap^(5, 7). The osteotomized head was fixed with headless screws, augmented with

absorbable sutures at the edges [Figure 3]. The head was visibly bleeding after fixation, which was an indication of the presence of vascular supply. A Dega osteotomy was also performed to improve the coverage of the smaller femoral head. The patient was placed in a spica cast for one month, and physical

therapy to regain range of motion was initiated afterwards.

At 3-year follow-up, the patient has minimal limp, 1.5cm of leg length inequality, and no pain. The range of hip motion is 0-120° of flexion, 30° of abduction, and a 45° arc of rotation. The femoral head is circular and well-contained [Figure 4].

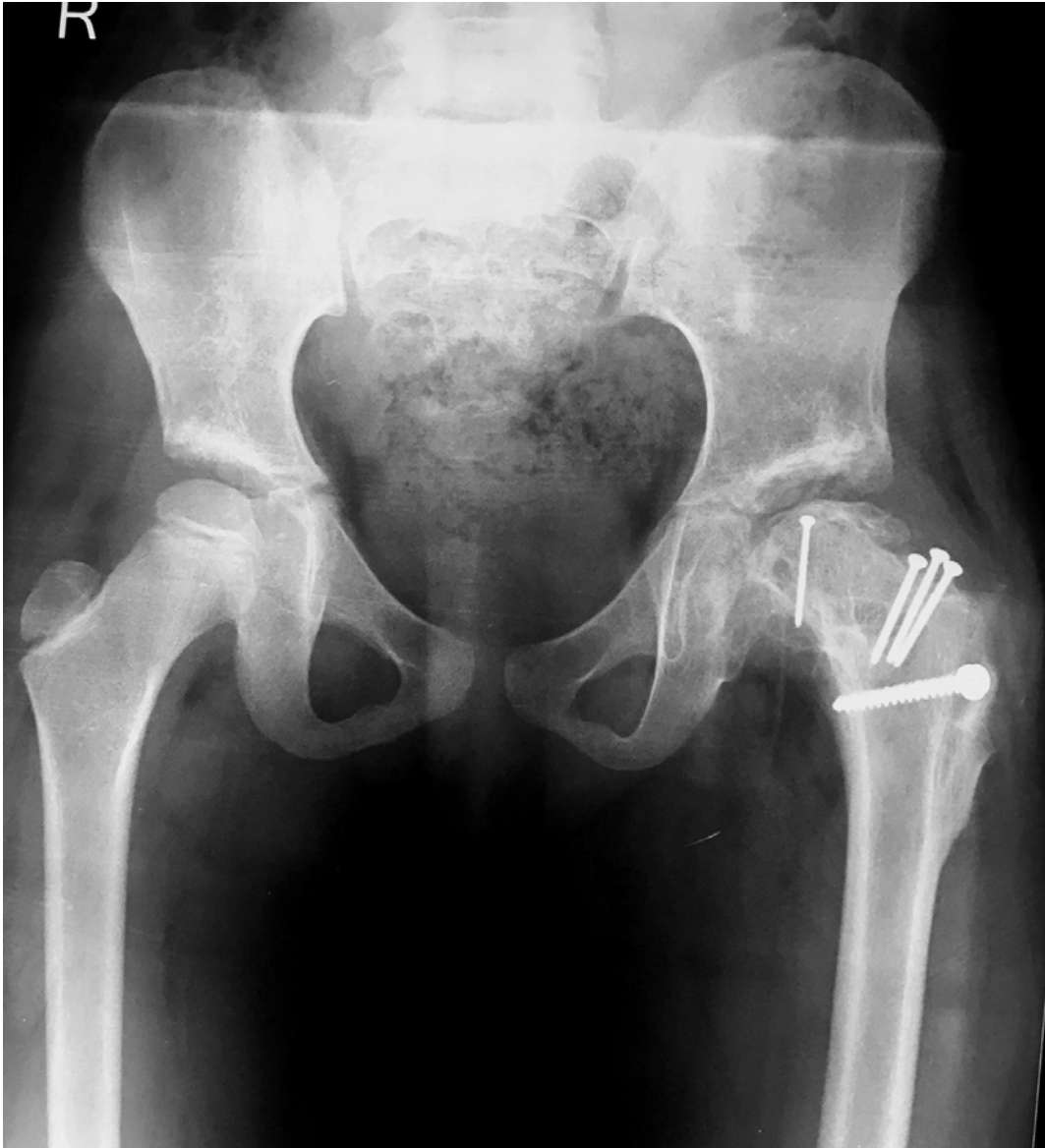

Figure 4 Post-operative x-ray. At 3-year follow-up standing radiograph, the femoral head is circular, with satisfactory acetabular coverage. The patient is painless and walking with minimal limp.

Discussion

Hip preservation surgery is usually reserved for the adolescent patient. Femoral head reduction osteotomies were devised for use in Perthes sequelae, which generally is after the age of 12. To the best of our knowledge, this is the first paper reporting a femoral head reduction osteotomy in a 6-year-old patient. Also, this is the first report of traumatic hip dislocation in an 18-month old child⁽⁸⁾.

Femoral head reduction osteotomy was introduced by Leunig and Ganz in 2011 as an 'intracapsular osteotomy' to treat long-term Perthes sequela⁽⁴⁾. After surgical dislocation of the hip, an extended retinacular flap is developed to protect the vascular structures. This is followed by the osteotomy of the head according to the pre-operative planning, which typically includes removal of the middle segment of the femoral head. When successful, long-standing satisfactory results have been reported by several authors, including mitigating the need for arthroplasty, decreasing pain levels, and improving patients' function and mobility⁽⁹⁻¹¹⁾. Complications are generally attributable to the primary pathology of the hip, with failure to alleviate pain and ROM limitations, conversion to total hip arthroplasty, and AVN of the femoral head being the most commonly reported complications^(5, 9, 12). The femoral head reduction osteotomy has a steep learning curve and is typically performed in referral centers with a high number of cases.

Several lessons were learned from this patient. In the smaller children, a generous incision is often needed to gain access to the acetabulum. The greater trochanter osteotomy should be performed with the utmost care, as most of the osteotomy is through the cartilage. A knife is more precise than the oscillating saw in the peripheries in younger children. The external rotators of the hip

are small, and maybe horizontal, rather than oblique in severe deformities with shorter necks.

Diligent preoperative planning is key to success in complex hip procedures. 3D-printed models have been extremely useful in our hands for such difficult cases. Most reports on the use of 3D models in the literature focus on planning the osteotomy on the computer screen⁽¹³⁾. While this is undoubtedly invaluable, it cannot replicate the situation at the time of operation. Therefore, following the case presented here, we have continued to simulate the surgeries on the physical 3D-printed models. This has proved to be a great educational tool for residents and fellows, as well as providing insight for the actual surgery.

It should be noted that these models are more fragile than the natural bone and break easily. This is more pronounced when working with Poly Lactic Acid (PLA) printed models, which are more nature-friendly and biodegradable, but also more fragile and less resistant to heat⁽¹⁴⁾. Acrylonitrile Butadiene Styrene (ABS) is also a commonly used material, which is less brittle and more heat-resistant than PLA. We have found that using a sharp, thin sawblade, and frequent cooling with water yields the best results when working with 3D-printed bone models. Also, when attempting screw fixation on the 3D-printed models, one should keep in mind that the torque tolerated by plastic is lower than bone, and overtightening of the screws would break the model easily.

There are several limitations to this study, including those inherent to case reports. First, this case was reported to illustrate that how a procedure typically reserved for adolescents and young adults can be successfully applied to children as young as 6 years old, and how novel technologies can aid the surgeon in

treating such cases. While this has not been reported before, the results should be replicated and validated in trials. In conclusion, the patient presented here suggests that hip preservation surgery principles could be applied to patients as young as 6-years-old. While the applications of femoral head reduction osteotomy is rare in this age group, with a thorough pre-operative evaluation and the use of modern surgical tools, including 3D-printed models, outcomes similar to that achieved in older patients could be expected.

Acknowledgements: None.

Ethics approval and consent to participate: According to the ethics committee of our institution, case reports do not need a formal ethics approval, and the need for an approval was waived.

Consent for publication: Written patient consent was obtained for publication of all aspects of the case, including personal and clinical details and images from the patient's legal guardians. The patient, which was a minor, gave her verbal assent to the study.

Disclosure: The authors report no conflict of interest concerning the materials or methods used in this study or the findings specified in this paper.

Authors' contributions: S.B. contributed to the conception of the work, manuscript writing, revision, and final approval of the manuscript. T.B. contributed to the patient's surgery, the conception of the work, revision, and final approval of the manuscript. S.B. and T.B. have read and approved the final version of the manuscript and take full responsibility for the accuracy and integrity of the work.

References

1. Vialle R, Odent T, Pannier S, Pauthier F, Laumonier F, Glorion C. Traumatic hip dislocation in childhood. *Journal of Pediatric Orthopaedics*. 2005;25(2):138-44.
2. Zrig M, Mnif H, Koubaa M, Abid A. Traumatic hip dislocation in children. *Acta Orthop Belg*. 2009;75(3):328.

3. Herrera-Soto JA, Price CT. Traumatic hip dislocations in children and adolescents: pitfalls and complications. *JAAOS-Journal of the American Academy of Orthopaedic Surgeons*. 2009;17(1):15-21.
4. Leunig M, Ganz R. Relative neck lengthening and intracapsular osteotomy for severe Perthes and Perthes-like deformities. *Bull NYU Hosp Jt Dis*. 2011;69(1):S62.
5. Paley D. The treatment of femoral head deformity and coxa magna by the Ganz femoral head reduction osteotomy. *Orthopedic Clinics*. 2011;42(3):389-99.
6. Ganz R, Gill T, Gautier E, Ganz K, Krügel N, Berlemann U. Surgical dislocation of the adult hip: a technique with full access to the femoral head and acetabulum without the risk of avascular necrosis. *The Journal of bone and joint surgery British volume*. 2001;83(8):1119-24.
7. Bartlett III CS, Birch CE. Femoral head reduction osteoplasty for fracture dislocation: a surgical technique. *Injury*. 2015;46(8):1689-94.
8. Baker JF, Leonard M, Devitt BM, Queally JM, Noel J. Traumatic hip dislocation in a 3-year-old girl. *Pediatr Emerg Care*. 2011;27(12):1178-9.
9. Georgiev H, Kehayov R, Georgiev GP. Surgical treatment of Stulberg V deformity of the hip joints in adolescents by Ganz femoral head reduction osteotomy. *Compt Rend Acad Bulg Sci*. 2015;68:267-73.
10. Siebenrock KA, Anwender H, Zurmühle CA, Tannast M, Slongo T, Steppacher SD. Head reduction osteotomy with additional containment surgery improves sphericity and containment and reduces pain in Legg-Calvé-Perthes disease. *Clinical Orthopaedics and Related Research®*. 2015;473(4):1274-83.
11. Novais EN. Application of the surgical dislocation approach to residual hip deformity secondary to Legg-Calvé-Perthes disease. *Journal of Pediatric Orthopaedics*. 2013;33:S62-S9.
12. Clohisy J, Pascual-Garrido C, Duncan S, Pashos G, Schoenecker P. Concurrent femoral head reduction and periacetabular osteotomies for the treatment of severe femoral head deformities. *Bone Joint J*. 2018;100(12):1551-8.
13. Kalenderer Ö, Erkuş S, Turgut A, Inan IH. Preoperative planning of femoral head reduction osteotomy using 3D printing model: A report of two cases. *Acta Orthop Traumatol Turc*. 2019;53(3):226-9.
14. Serra T, Planell JA, Navarro M. High-resolution PLA-based composite scaffolds via 3-D printing technology. *Acta biomaterialia*. 2013;9(3):5521-30.