

The Effect of Hydroalcoholic Extract of Tarantula Cubensis on the Distal Radius Fracture Healing in Rabbits

Abstract

Background: Nowadays, bone grafts are used in both veterinary and human orthopaedics to stimulate fracture healing and to accelerate the restoration of bone defects. Autografts are still a high standard for comparing different bone-building stimuli. Autografts not only include healing stimulants but also contains cells that do not stimulate immune responses and do not transmit infectious diseases. However, bone grafting is not without side effects such as pain, infection, fracture, blood loss and increased surgical stages, besides the amount of bone removed is limited.

Tarantula cubensis venom has an anti-inflammatory and re-epithelialization effect in bovine wound healing on the 14th day; it also plays a role in infection prevention since Theranekron can alter the process of inflammation. This study aims to examine the effect of hydroalcoholic extract of tarantula cubensis on the distal radius fracture healing in rabbits

Methods: This study was conducted on 20 male rabbits, in four study groups of five rabbits. A bone se was extracted from the distal radius. The first group was administrated with one microgram per kilogram of Theranekron injection at the site of the bone defection. The second and third (or negative control) groups were administrated with normal saline injection and no substance (no intervention), respectively. Lastly, the fourth group (or autograft group), the extracted bone segment was returned in its place, and the skin and muscles were sutured. Lateral view radiographs images were taken from rabbits on days of 14, 28, 42 and 56 after surgery.

On the eighth week, a bone biopsy was performed to evaluate histopathology. Radiographs and biopsies were statistically examined for fusion rate, ossification activity and remodelling.

Results and Conclusion: Both Theranekron and autograft group had similar behaviour and outperformed the normal saline and negative control group; therefore it is concluded that hydroalcoholic extract of tarantula cubensis was effective in distal radius fracture healing.

Keywords: Rabbit, Fracture Healing, Tarantula Venom, Radius Fractures, Spiders

Received: 6 months before printing; Accepted: 2 Months before printing

Siavash Sharifi*, Amin Beigham-Sadegh**, Ahmad Oryan***, Yasmin Alavi**

* ¹ Assistant Professor,
Department of Surgery and
Radiology, Shahrekord
University

¹ *Corresponding Author,
Professor, Department of
Surgery and Radiology,
Shahrekord University and
Professor, Department of
Surgery and Radiology,
Faculty of Veterinary
Medicine, Shiraz
University, Postal Code:
8818634141, PO Box: 115,
e-mail:
dr.bigham@gmail.com

¹ Professor, Department of
Pathology, Shiraz

¹ Graduated in general
veterinarian

Introduction

Distal Nowadays, bone grafts are used in both veterinary and human orthopaedics to stimulate fracture healing and to accelerate the restoration of bone defects. Autografts are still a high standard for comparing different bone-building stimuli. Autografts not only include healing stimulants but also contains cells that do not stimulate immune responses and do not transmit infectious diseases ⁽¹⁾. Bone grafting in small animals is extracted from the ileum, the inner surface of the upper part of the tibia and the upper end of the humerus. This procedure applies to humans from the ileum.

not without side effects such as pain, infection, fracture, blood loss and increased amount of bone removed is limited ⁽²⁾. Currently, due to the above mentioned side growing tendency toward using non-native bone resections such as allografts and limitation to the amount of extraction for non-native bone resections; they ing scaffold in large bone fissures such as tumour resection and loss of bone tissue increase the risk of transmitting infectious diseases.

Tarantula cubensis is an extract that is widely used in the treatment of tumours, abscesses, sepsis and toxic diseases⁽⁴⁻⁶⁾. It is also known for its anti-inflammatory and re-epithelialization effect in bovine wound healing on the 14th day^(7,8) and extensive infection prevention properties^(9,10). Tarantula cubensis is a species of mygalomorph spider, also known as mygalomorph cubensis, brown spider and hairy spider⁽¹¹⁾. This large spider is native to South Carolina, Texas and Cuba has a dark brown hairy body and is less toxic than Tarentula hispanica. The initial composition of the extract, the main ingredient of which is Arachnid, is taken from the body of the spider⁽¹¹⁾. The spider is crushed, then its alcoholic extract is removed and sold commercially under the name Theranekron.

Cam et al. (2007) compared the effect of levamisole and Theranekron on bovine cutaneous papillomatosis and concluded that levamisole was more effective⁽¹⁰⁾. Gultiken and Vural (2007) investigated the effect of Theranekron on canine mammary tumours and discovered its healing effect on benign tumours⁽⁵⁾.

Albay et al. (2010) studied the influence of tarantula cubensis extract on the treatment of the oral lesions in cattle with bluetongue disease, they determined short term effect (after 24hrs) of Theranekron improved appetite, reduced inflammation of the mouth ulcers, and is accompanied by a decrease in leukocytes and lymphocytes in the blood plate. Therefore, after ten days, there is no change in clinical symptoms, and leukocyte count and only a significant change in lymphocyte count were observed⁽⁸⁾.

Sardari et al. (2011) evaluated the effect of Theranekron serum on haematology and biochemical properties of serum in horses; they concluded that most of the observed changes in haematological and biochemical parameters were statistically significant; therefore administration of Theranekron in the horses did not cause any adverse reactions⁽⁷⁾. Oryan et al. (2012) examined the application of Theranekron on the damaged tendon, which enhanced the biomechanical parameters⁽¹²⁾.

Adib-Hashemi investigated the anti-inflammatory and protective effect of Theranekron invasion in peritoneal wound healing in rats, in which histopathological tests showed progress in angiogenesis, epithelial regeneration, and less inflammatory response compared to the control group. Furthermore, mature collagen fibres were parallel and dense after 29 days⁽¹³⁾. This study aimed to evaluate the effect of Theranekron on bone fracture healing since it can alter the inflammatory process.

Methods

This study selected 20 native male rabbits weighing approximately 2 kg and aged 1.5 to 2 years for surgery. Rabbits were kept in specific cages and fed with specific food for 15 days to get accustomed to the new conditions. The conditions were identical for all the rabbits. In order to exterminate internal and external parasites such as roundworms, rabbits were administrated with subcutaneously with the antiparasitic drug ivermectin (produced by Royan Daru Company, 50 ml vials) at a dose of 0.2 mg/kg. Rabbits were distributed into four groups of five. The first group was administrated with 1 mg/ml of Theranekron diluted in 0.9% normal saline and injected at a dose of 1 µg/kg at the defected bone on 3, 5 and 7 days after the surgery⁽¹⁴⁾. The second group (saline control) was administrated with normal saline and Theranekron (produced by Daroopakhsh, 50 ml vials) and injected according to plan. The third or negative control group was administrated with no substance. The fourth or autograft group, the removed fragment was returned in its place, and the skin and muscles were sutured.

Rabbits were sedated with 0.2 mg/kg of acepromazine (produced by Alfasan Co. of Netherland, in 100 ml vials of 2%), then were anaesthetized intramuscularly by a combination of 30 Mg/Kg of ketamine (produced by Alfasan Co. of Netherland, in 100 ml vials of 10%), 5 Mg/Kg of xylazine (produced by Alfasan Co. of Netherland, in 50 ml vials of 2%) and 4 Mg/Kg of diazepam (manufactured by Caspian Tamin, in 2 ml vials

of 10 mg). Their right hand was shaved and prepared for the surgery. After implantation, a skin incision was made in the anterior-medial surface on the radius bone, and the radius bone was exposed by removing the soft tissues and muscles.

Two incisions were made in the radius bone with an orthopaedic chainsaw, and then a piece of bone twice its width (approximately 10 mm) was removed from the midline of the radius bone. After that, the skin was sutured as a simple single piece with double nylon thread (Fig 1).

The research process stopped until the rabbits fully recovered from anaesthesia; then they were released into cages without external fixation. In order to prevent postoperative infection, the rabbits were injected intramuscularly with the 5 mg/kg of antibiotic enrofloxacin (produced by Royandaro, in 50 ml vial at 10%) daily for three consecutive days.

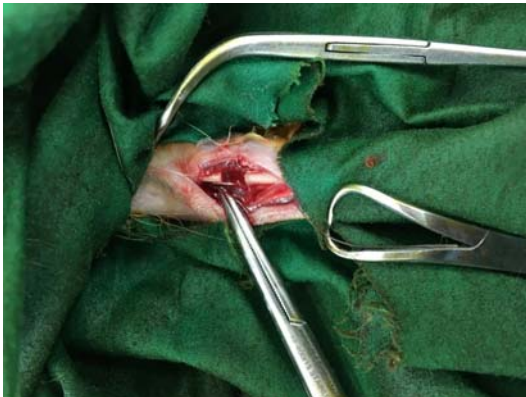

Fig 1- Creating bone defects for injection of Theranekron with an orthopaedic chainsaw

Methods:

For clinical purposes, the rabbits were examined twice a day for the following items: the site of operation, how they used their hand, weight, local wounds, inflammation, and infection. Lateral view radiographs were taken from rabbits immediately after the operation and 14, 28, 42, and 56 days after the surgery. It should be noted that the X-ray source (Siemens X-ray device, made in Germany) was placed 70 cm away from the film and the radiograph was set at 45 kV and 20 mAs. To evaluate and grade the

radiographs prepared from the deformation on the 56th day, all rabbits were exterminated by the human method after induction of anaesthesia by injection of high magnesium sulfate in the form of intracardiac injection. Then we removed the radius bone of each rabbit and separated all the soft tissues around it from the bone.

Defective bones were placed in 10% Merck formaldehyde solution for histopathological evaluation and sent to the laboratory. The samples were soaked in 10% formaldehyde solution for 24 hours; then the solution was substituted and re-soaked in formalin until a fixed time. Then the bone was demineralized by placing in 10% organic acid (nitric acid) for four days. The samples were then washed with water and processed by an Autotechnicon. Then it was sent to histopathology laboratory and examined by light microscope to prepare for microscopic slides. The histopathological evaluation used bone healing scoring method⁽¹⁶⁾.

Statistical Analysis

Data were analyzed by SPSS software version 19. The results were statistically evaluated by Kruskal-Wallis non-parametric ANOVA test where the p-value was less than 0.05. After a retest by Mann-Whitney method, all the p-values less than 0.05 was considered to be statistically significant.

Results

There was no case of infection at the surgical site. Radiographic evaluation of the healing process in rabbits was performed in four groups of autograft, Theranekron, negative control and standard saline control on days of 14, 28, 42 and 56 after surgery. Grading was performed in terms of bone formation, upper and lower fusion rates, and bone remodelling (reconstruction) (Table 1 and Fig 2-5).

Fifty-six days after the operation, the radius bone was removed, and the isolated samples were referred to the laboratory for histopathological evaluation according to the bone healing grading system⁽¹⁶⁾. The histopathological evaluation did not indicate any signs of inflammation or infection in the

Table 1: Results obtained from the radiographic evaluation (total evaluation criteria) in different weeks

Group Week	Negative control Mean (min-max)	Autograft Mean (min-max)	Normal saline control Mean (min-max)	Theranechron Mean (min-max)	P ^a
Second	0 (1-0)	5 (1-5) ^b	1 (0-1)	1 (0-2) ^c	0.02
Fourth	1 (1-6)	5 (5-9) ^d	1 (0-5)	5 (2-9) ^e	0.01
Sixth	1 (1-6)	5 (5-10) ^f	1 (0-5)	9 (8-9) ^g	0.004
Eighth	4 (1-9)	10 (9-10) ^h	1 (0-8)	8 (1-8)	0.005

^a Kruskal- Wallis non-parametric ANOVA

^b The autograft group had a significant difference with the negative control group p-value=0.02 and the normal saline control group p-value=0.04.

^c Theranechron group had a significant difference with negative control group p-value=0.04.

^d The autograft group had a significant difference with the normal saline control group p-value=0.01.

^e Theranechron group significantly associated with negative control group p-value=0.03 and normal saline control group p-value=0.02.

^f The autograft group significantly associated with the normal saline control group p-value=0.01.

^g Theranechron group significantly associated with negative control group p-value=0.006 and normal saline control group p-value=0.008.

^h The autograft group significantly outperformed the negative control group p-value=0.009, the normal saline control group p-value=0.006, and the Theranechron group p-value=0.006.

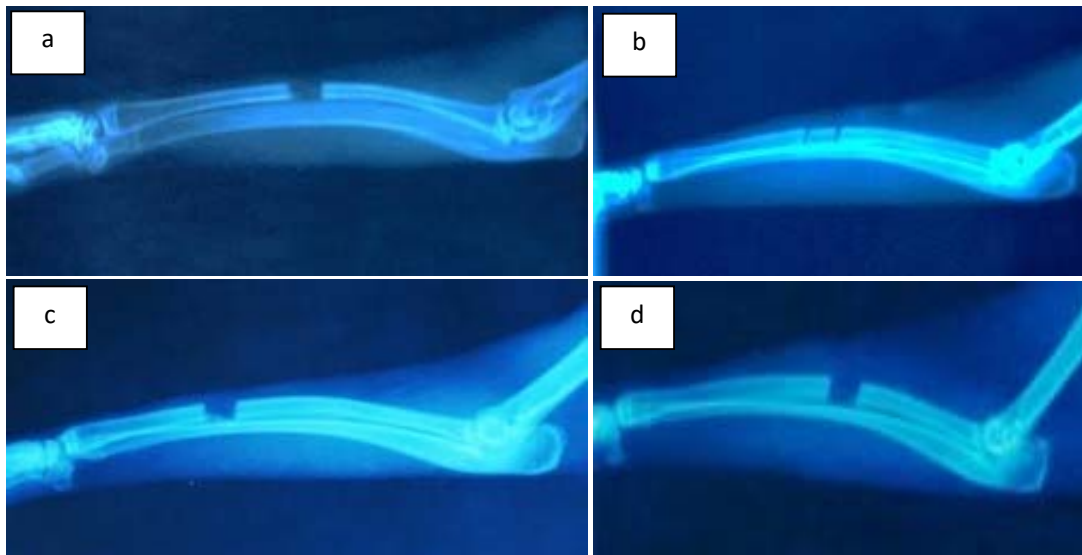


Fig 2 - The second-week radiographs: (a) Theranechron, (b) autograft group, (c) normal saline control group, (d) negative control group

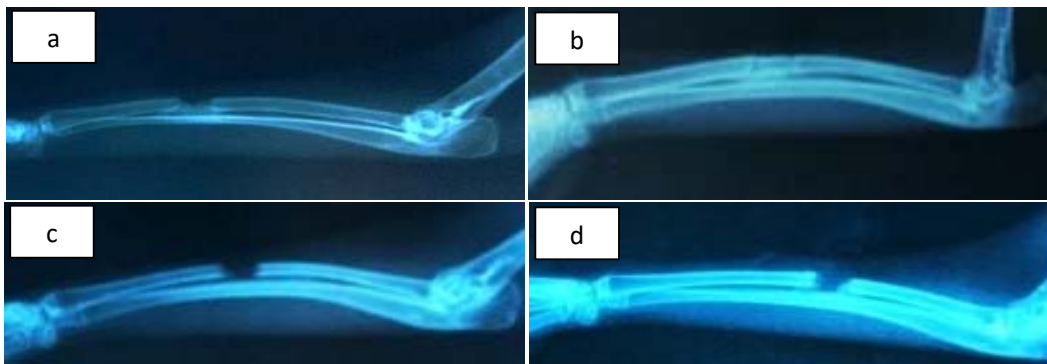


Fig 3 - The eighth-week radiographs: (a) Theranechron, (b) autograft group, (c) normal saline control group, (d) negative control group

rabbits. Moreover, the formation of trabecular bone and bone marrow were indicated for Theranekron group. In the normal saline and negative control groups, most of the defect was filled with

fibrous tissue; finally, the formation of the thick trabecular bone and bone marrow were observed in the autograft group.

Table 2 - Results obtained from the histopathological evaluation				
Negative control Mean (min-max)	Autograft Mean (min-max)	Normal saline control Mean (min-max)	Theranekron Mean (min-max)	P ^a
1 (0-3) ^b	6 (2-6)	1 (1-7)	5 (2-6)	0.05

^a Kruskal- Wallis non-parametric ANOVA

^b Negative control group had a significant difference with autograft group p-value=0.04 and Theranekron group p-value=0.04.

Similar to the radiologic evaluations, the initial and supplementary histopathological results were obtained by Kruskal-Wallis non-parametric ANOVA test and Mann-Whitney U test. Given the results, a significant difference was observed between the negative control group compared with the autograft (p-value=0.04) and the Theranekron group (as presented in Table 2 and Fig 6-9).

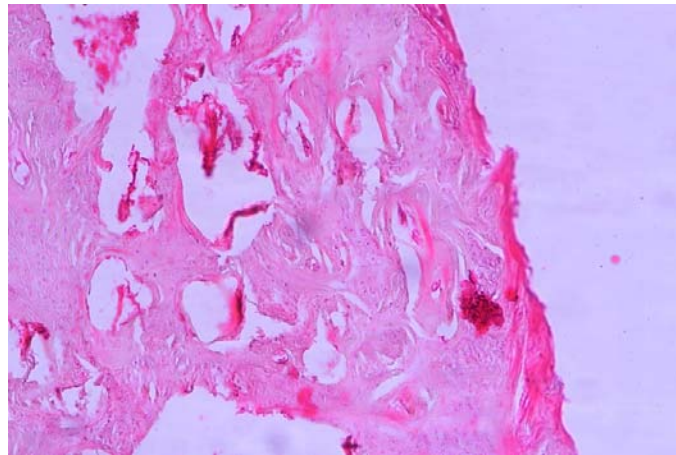


Fig 4 - Histopathological signs of Theranekron group, the formation of trabecular bone (indicated with yellow arrow). H&E histology image, x10 zoom.

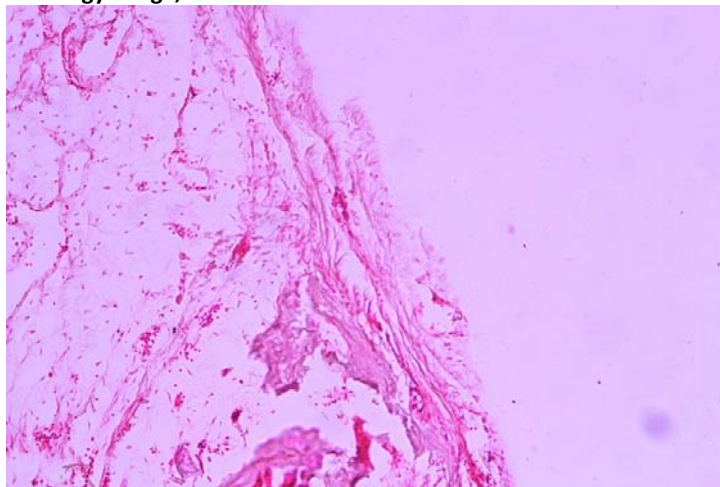


Fig 5 - Histopathological symptoms of the normal saline control group, the formation of fibrous tissue (indicated with yellow arrow). H&E histology image, x10 zoom.

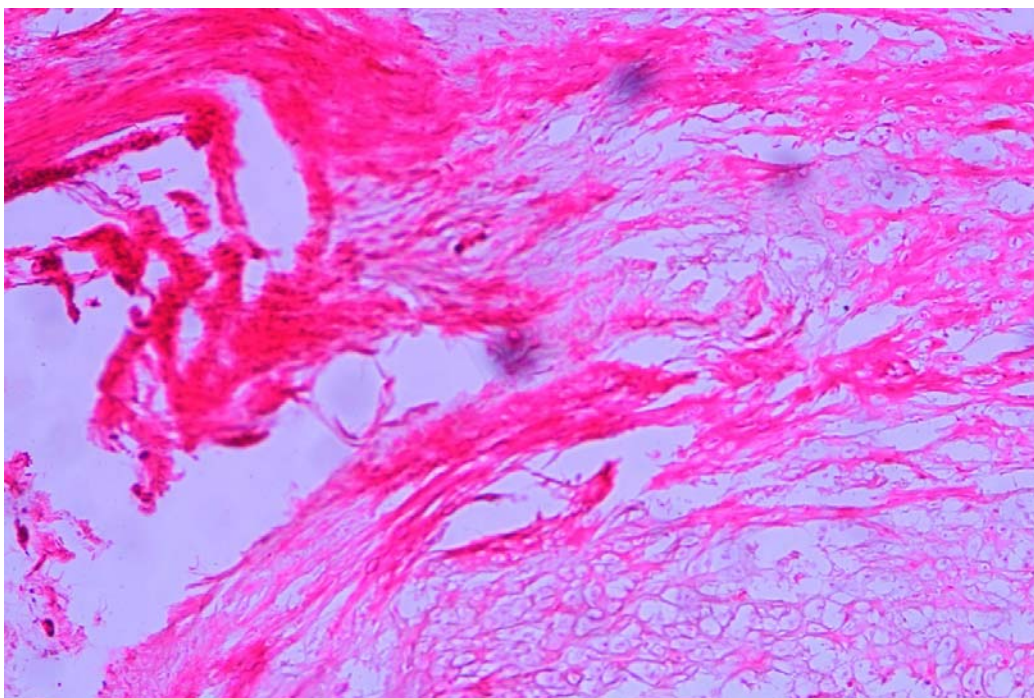
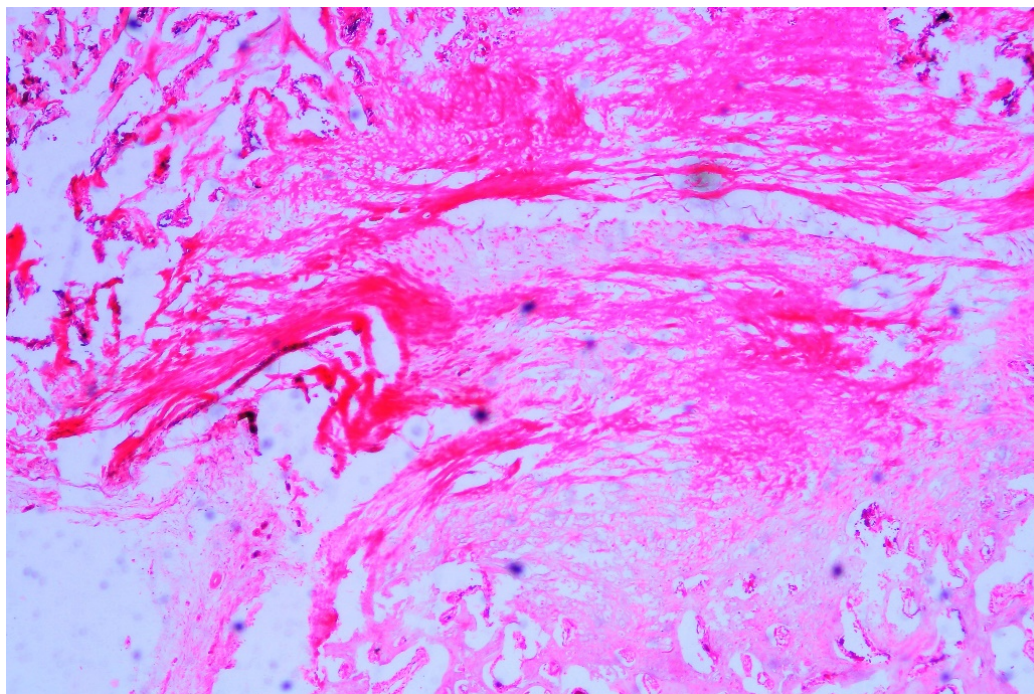


Fig 6 - Histopathological symptoms of the negative control group, the formation of fibrous tissue (indicated with yellow arrow). H&E histology image, x4 zoom (a) and x10 zoom (b)

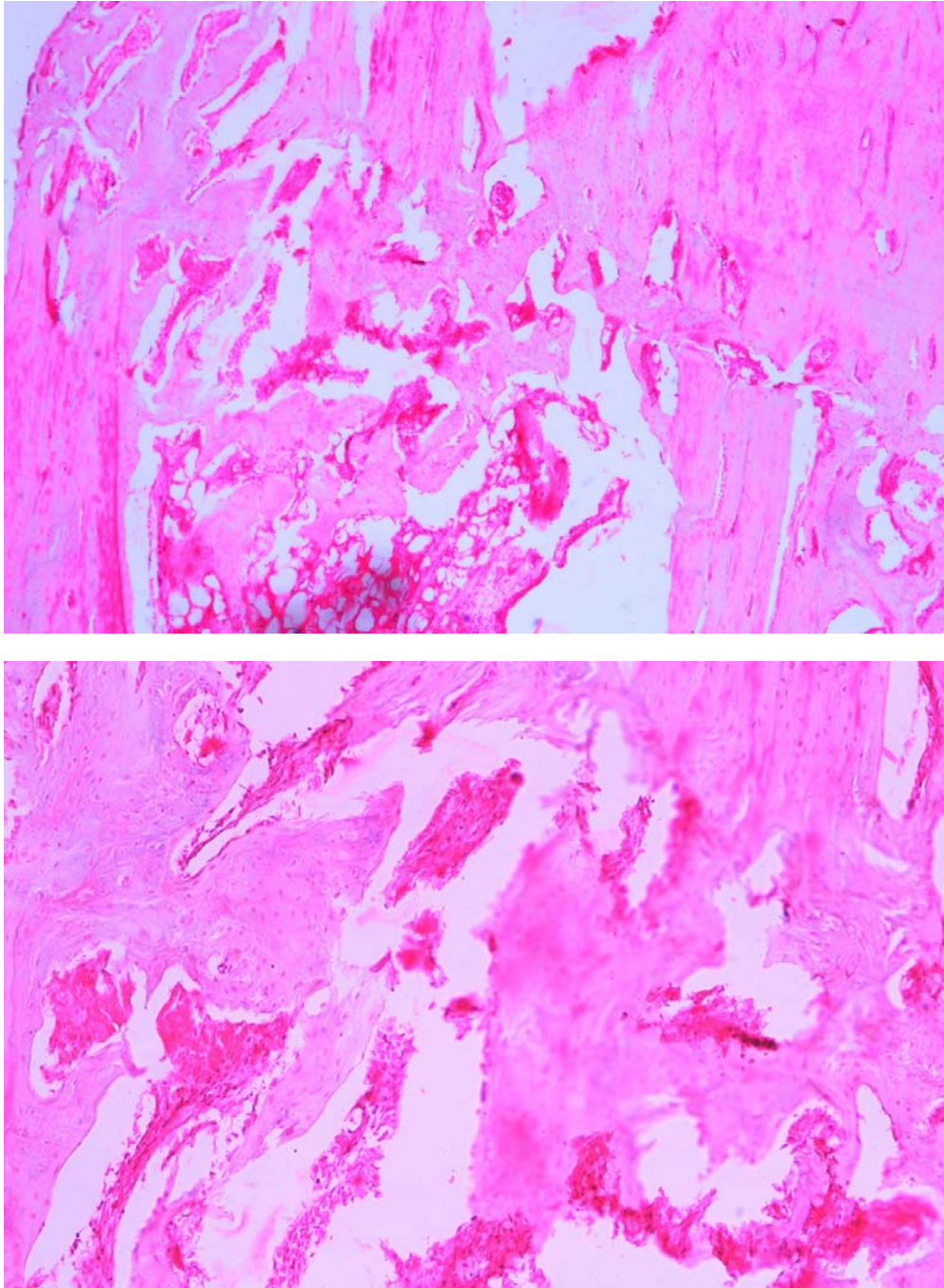


Fig 7 - Histopathological symptoms of autograft group, the formation of bone marrow (indicated with yellow arrow), the formation of thick trabecular bone (indicated with white arrow). H&E histology image, x4 zoom (a) and x10 zoom (b).

Conclusion

Conclusion

This study was performed on rabbits rather than *Rattus* since the rabbits' Haversian system of long bones is similar to humans, and it is a better model to study the process

of fracture healing⁽¹⁷⁾. The radius bone of forearm was selected to compare the autografts in the rabbit, due to the connection between the forearm and the ulna removing a fragment of this bone does not need a stabilizer, and therefore it is possible to examine the healing process without any

external factor⁽¹⁸⁾. The bone defect was created on the middle part of the radius, and the length of the removed fragment was twice the width of the bone diaphysis in order to build a non-connective model⁽¹⁹⁾. The autograft group was the best in this study in terms of healing pace; only Theranekron group showed similar performance.

Bone autografting is considered as a high standard for comparison of other bone-stimulating factors. In addition to stimulants, autograft contains cells that do not stimulate immune responses and do not transmit infectious diseases⁽¹⁾.

Bone grafting in small animals is extracted from the ileum, the inner surface of the upper part of the tibia and the upper end of the humerus. This procedure applies to humans from the ileum. However, bone grafting is not without side effects such as pain, infection, fracture, blood loss and increased surgical stages, besides the amount of bone removed is limited⁽²⁾.

Autograft transplantation is considered as a lively control group in various studies as well as present research. The performance of Theranekron and autograft group were almost identical, which outperformed both normal saline and negative control groups. The beneficial effect of Theranekron on bone healing may be due to its anti-inflammatory impact on post-surgical necrosis and the regulation of the fibroplasia stage of healing⁽²⁰⁾. Beigham-Sadegh et al. investigated the impact of Theranekron and hydroxyapatite on the healing of rabbit bone defects, which yielded positive outcomes⁽²¹⁾.

Orian et al. examined the impact of Theranekron on tendon repair by comparing the control group to the intervention group; they observed positive results such as weight gain, improved motor ability, and reduction of tissue inflammation which is due to anti-inflammatory properties of Theranekron that led to the reduction of oedema, necrosis, and pain⁽¹⁴⁾.

Adib Hashemi et al. concluded that the compared to the control group, the Theranekron group had significantly lower and higher levels of collagen and inflammatory cells, respectively. Moreover,

histopathological tests showed progress in granuloma angiogenesis⁽²²⁾.

Anti-inflammatory properties are one of the most noticeable effects of Theranekron. Inflammation is essential for building the mediators that trigger the regeneration and healing process. Adminstrating Theranekron can control this effect during inflammation⁽²³⁾. Some anti-inflammatory properties in Theranekron can be attributed to its ability to prevent additional inflammation that led to tissue repair⁽¹⁴⁾. Chronic inflammation can result in cell destruction by stabilizing involvement in Polymorphonuclear Leukocytes (PMNs).

The primary role of PMNs is protection against microorganisms; it also absorbs mononuclear cells and phagocytoses fibrinous and debris. It should be noted that lysosomal enzymes released by PMNs are involved in the destruction of debridements⁽²⁴⁾.

Limitations of the study

The main limitation was the lack of biomechanical testing in the samples, which required a large number of animals as the study population. It was recommended to have CT scan images from the repair site and compare the quantitative ossification volume slightly between groups, which unfortunately was not possible.

It is believed that Theranekron can release digestive peptides that specify necrotic tissues⁽²⁵⁾. This feature can separate dead tissue from living tissue and intensify differentiation at the cellular level⁽¹⁴⁾.

Given the histopathological results and radiographs, the bone defect of the normal saline group and negative control group was filled with fibrous tissue, which prevented the bone formation⁽²⁵⁾. Therefore, the Theranekron group had faster bone formation; the present study indicated the bone healing impact of Theranekron in rabbits.

References

1. Fitch, R., et al., *Bone autografts and allografts in dogs*. *Compend Contin Educ Vet*, 1997. **19**(5): p. 558-578.
2. Ferguson, J.F., *Fracture of the humerus after cancellous hone graft harvesting in a dog*. *J Small*

- Anim Pract, 1996. **37**(5): p. 232-234.
- 3.Dorea, H.C., et al.,** Evaluation of healing in feline femoral defects filled with cancellous autograft, cancellous allograft or Bioglass. Vet Comp Orthop Traumatol, 2005. **18**(3): p. 157-168.
- 4.Stampa, S.,** A field trial comparing the efficacy of sulphamonomethoxine, penicillin, and tarantula poison in the treatment of pododermatitis circumscripta of the cattle. J S AFR VET ASSOC, 1986. **57**(2): p. 91-93.
- 5.Gultiken, N. and M.R. Vural,** The effect of *Tarantula cubensis* extract applied in pre and postoperative period of canine mammary tumours. J Istanbul Vet Science, 2007. **2**: p. 13-23.
- 6.Muste, A., et al.,** Morphoclinical aspects in tarsal bursitis in cattles; surgical and medicamentous treatment. Bulletin UASVM Horticulture, 2008. **65**(2).
- 7.Sardari, K., E.G. Kakhki, and M. Mohri,** Evaluation of wound contraction and epithelialization after subcutaneous administration of Theranekron[®] in cows. Comp Clin Path, 2007. **16**(3): p. 197-200.
- 8.Albay, M.K., et al.,** Influence of *Tarantula cubensis* extract on the treatment of the oral lesions in cattle with bluetongue disease. Kafkas Univ Vet Fak Derg 2010. **16**: p. 593-596.
- 9.Kacar, C., et al.,** The effects of Theranekron (R) application on uterus involution and vaginal effluence in cows early puerperal period. Kafkas Univ Vet Fak Derg 2007. **13**(1): p. 11-15.
- 10.Cam, Y., et al.,** Efficacy of levamisole and *Tarantula cubensis* venom for the treatment of bovine cutaneous papillomatosis. Vet Rec, 2007. **160**(14): p. 486-488.
- 11.Richardson-Boedler, C.,** The brown spider *Loxosceles laeta*: source of the remedy *Tarentula cubensis*? Homeopathy, 2002. **91**(3): p. 166-170.
- 12.Oryan, A., A. Moshiri, and A.R. Raayat,** Novel application of Theranekron[®] enhanced the structural and functional performance of the tenotomized tendon in rabbits. Cells Tissues Organs, 2012. **196**(5): p. 442-455.
- 13.Adib-Hashemi, F., et al.,** Anti-inflammatory and protective investigations on the effects of Theranekron an alcoholic extract of the *Tarantula cubensis* on wound healing of peritoneal in the rat: an in vivo comparative study. Diagn Pathol, 2015. **10**(1): p. 19.
- 14.Bigham-Sadegh, A., et al.,** Effects of adipose tissue stem cell concurrent with greater omentum on experimental long-bone healing in dog. Connective tissue research, 2012. **53**(4): p. 334-342.
- 15.Lane, J.M. and H. Sandhu,** Current approaches to experimental bone grafting. The Orthopedic clinics of North America, 1987. **18**(2): p. 213-225.
- 16.Bigham-Sadegh, A. and A. Oryan,** Selection of animal models for pre-clinical strategies in evaluating the fracture healing, bone graft substitutes and bone tissue regeneration and engineering. Connective tissue research, 2015. **56**(3): p. 175-194.
- 17.Matos, M.A., F.P. Araújo, and F.B. Paixão,** Histomorphometric evaluation of bone healing in rabbit fibular osteotomy model without fixation. Journal of orthopaedic surgery and research, 2008. **3**(1): p. 1.
- 18.An, Y.H. and R.J. Friedman,** Animal models in orthopedic Research 1ed. 1999: CRC Press.
- 19.Bolander, M.E. and G. Galian,** The use of demineralize bone matrix in the repair of segmental defect. Journal of Bone and Joint Surgery, 1986. **68A**: p. 1264-1274.
- 20.Enbergs, H. and B. Sensen,** Effectiveness of a homeopathic treatment of chronic endometritis in dairy cows. Praktische Tierarzt, 2007. **88**(7): p. 534-+.
- 21.BighamSadegh, A., et al.,** Concurrent Use of Theranekron with Hydroxyapatite on Bone Healing in Rabbit Model: Radiographic and Histologic Evaluation. Iranian Journal of Orthopaedic Surgery, 2017. **15**(2): p. 56-64.
- 22.Adib-Hashemi, F., et al.,** Anti-inflammatory and protective investigations on the effects of Theranekron[®] an alcoholic extract of the *Tarantula cubensis* on wound healing of peritoneal in the rat: an in vivo comparative study. Diagnostic pathology, 2015. **10**(1): p. 1.
- 23.LOZIER, S. and J. HARARI,** Surgical complications and wound healing in the small animal practice. Surgical complications and wound healing in the small animal practice, 1993.
- 24.Sardari, K., E.G. Kakhki, and M. Mohri,** Evaluation of wound contraction and epithelialization after subcutaneous administration of Theranekron[®] in cows. Comparative Clinical Pathology, 2007. **16**(3): p. 197-200.
- 25.Oryan, A., A. Bigham-Sadegh, and F. Abbasi-Teshnizi,** Effects of osteogenic medium on healing of the experimental critical bone defect in