

Comparison of Prophylactic Short-Term Use of Enoxaparin and Rivaroxaban after Total Knee Replacement Surgery

Abstract

Background: Venous thromboembolism (VTE) increases patient's morbidity and mortality after orthopedic surgeries, and as such, prophylaxis is a routine practice after total joint replacement. Although there are many effective and safe prophylactic agents, clinical results are suboptimal. The aim of this study was to compare clinical and ultrasonographic results for the use of low molecule weight heparin (LMWH) and Rivaroxaban in patients undergoing total knee replacement.

Methods: In a prospective cross-sectional study 325 patients were enrolled in receiving Enoxaparin or Rivaroxaban as thromboprophylaxis in their total knee replacement surgery. They had pre and post-operative doppler ultrasonography for diagnosis of thromboembolism. They were followed for a minimum of two years. The status and occurrence of VTE was evaluated. Patients were compared in terms of gender, body mass index (BMI), smoking, diabetes mellitus (DM) and previous VTE history.

Results: The 325 eligible patients provided a sample of 130 (40%) male and 195 (60%) female. The average patient age (SD) was 63.2 (14.3). A total of 40 (12.3%) patients (27 on LMWH, and 13 on Rivaroxaban), had DVT at the lower extremity. 15 (4.6 %) patients-11 from LMWH and 4 from Rivaroxaban group had pulmonary embolism (PE). 5 patients (1.5%) -4 on LMWH, 1 on Rivaroxaban- had cerebrovascular thromboembolism. The incidence of thromboembolism was found to be similar in both prophylactic regimes. On the other hand, 2 patients (0.6%) had spontaneous retroperitoneal bleeding from LMWH group. The PE patients had history of DVT. DVT occurred in patients with risk factors of obesity, diabetes or smoking.

Conclusion: There was no difference between the use of rivaroxaban and enoxaparin for thromboembolic prophylaxis in total knee replacement in terms of occurrence of venous thrombosis and PE. Long-term thromboembolic prophylactic is preferred in cases with smoking, diabetes and obesity. Patients with previous venous thromboembolism are at a high risk for pulmonary and cerebrovascular embolism. Progressive hematocrit drop should alert the surgeon towards spontaneous retroperitoneal bleeding in the patients taking enoxaparin for thromboprophylaxis after total knee replacement surgery.

Key words: Total Knee Replacement (TKR), Deep Venous Thrombosis, Rivaroxaban, Low Molecule Weight Heparin (LMWH)

Received: 2 months before printing; Accepted: 2 month before printing

* Omer, Ozel ,MD; **Dogac, Karaguvan ,MD; I. *Teoman, Benli, Prof.

* Orthopaedic Surgeon,
Medical School of Baskent
University Department of
Orthopaedics, Istanbul/
Turkey

** Orthopaedic Surgeon,
Medical School of Ufuk
University Department of
Orthopaedics, Ankara,
Turkey.

* Correspondence

Omer, Ozel (MD)

Email Address:
dromerozel@gmail.com

Introduction

Hip and knee replacements are surgical interventions that increase patient quality of life. Total knee replacement is one of the commonly performed surgeries in America ⁽¹⁾. Unfortunately, venous thromboembolic diseases, with cause for increase in morbidity and mortality, are also seen with these procedures ^(2,3). The prevalence of asymptomatic deep venous thrombosis (DVT) is 16-30 % in spite of pharmacological and mechanical agents ⁽²⁾. Although the fatal pulmonary embolism rate has decreased, symptomatic DVT is seen at rates of 1.7-2.3 % after total knee and hip replacement ⁽⁴⁾. Coagulation disorders, smoking, obesity, advanced age, multiple trauma, malignancy, venous thromboembolic disease history

and/or long-term immobilization are factors increasing DVT risk⁽⁵⁾. The use of tourniquets, polymethyl-metacrylate (PMMA) bone cement and extremity manipulations during orthopedic surgeries also increase the risk of DVT due to vascular injury and elevated thromboplastin activity⁽⁵⁾.

Venography is the gold standard for the diagnosis of DVT. However, it is not the first choice as it is an invasive procedure⁽⁶⁾. Doppler ultrasonography (USG) is an alternative simple, non-invasive method for venous flow control and thrombus detection, especially for the distal venous system. This meta-analysis⁽⁷⁾ showed that the sensitivity of Doppler USG for a proximal and distal venous system was 63.5% and 94.2%, respectively. Accordingly, it is the most commonly used noninvasive test in clinical practice. Computed tomography (CT) venography is non-invasive, highly specific and sensitive for DVT. It has adverse effects depending on the contrast injection as conventional venography. It may be more reliable for PE patients who are suspected to have proximal DVT⁽⁸⁾.

Prophylaxis against venous thromboembolism (VTE) is a routine practice after total joint replacement surgery. Although there are many effective and safe prophylactic agents, clinical outcomes are suboptimal⁽⁹⁾. The ideal prophylactic regimen should be effective, inexpensive and safe⁽¹⁰⁾.

In patients with total knee replacement, the American College of Chest Physicians (ACCP)⁽¹¹⁾ recommends 10-14 days of thromboprophylaxis if there is no contraindication. Low molecule weight heparin (LMWH) is a subcutaneous agent that inhibits Factor Xa indirectly via antithrombin. Rivaroxaban is a relatively new pharmacological agent that inhibits prothrombin activity by direct inhibition of Factor Xa⁽¹²⁾. The popularity of oral anticoagulants is expanding as an alternative and non-invasive option to classical LMWH. Moreover, the once-a-day oral administration and lack of a monitoring requirement for the

patient are favorable in terms of patient compliance and tolerance⁽¹³⁾.

In addition to these agents, or in cases where the use of antithrombotic agents is risky, an intermittent pneumatic compression device (IPCD) is recommended⁽¹⁴⁾. Currently, there is no worldwide consensus regarding an antithrombotic treatment protocol that has a high level of evidence regarding its effectiveness and the duration of its application. In this study, clinical and radiological results of LMWH and rivaroxaban were examined after total knee replacement (TKR) and risk factors of LMWH and rivaroxaban were compared in patients who underwent total knee replacement surgery.

Methods

This study was planned as a prospective cross-sectional study. Ethical committee approval (2010/HH-KAEK-0007) was obtained prior to this study. Patients were provided with details regarding treatment and possible complications. Signed informed consent forms were obtained from all participants.

We prospectively investigated patients who underwent unilateral cemented posterior cruciate ligament (PCL) excised total knee replacement between January 2010 and January 2018 that also had a minimum two years of follow-up (Table-1). The thromboprophylaxis regime was changed by the end of every year and eligible patients taken to proper group.

Patients with malignancy, heart disease, blood coagulation disorder, estrogen therapy history, patients who could not be mobilized on the postoperative second day, and patients whose tourniquet duration was longer than two hours were excluded from the study. The eligible 325 patients were divided into LMWH and rivaroxaban groups according to the applied thromboprophylaxis. In the LMWH group of patients, enoxaparin sodium 4000 IU (Clexane; Sanofi Corp., Paris, France) was administered subcutaneously for 10 days, starting 12 hours

before surgery⁽¹⁵⁾. In the rivaroxaban group, only rivaroxaban 15 mg (Xarelto; Bayer, Leverkusen, Germany) was given orally once a day for 10 days, starting 6-10 hours after surgery⁽¹⁴⁾. The patients were compared in terms of occurrence of DVT, Pulmonary Embolism (PE), and Cerebrovascular Thromboembolism (CVT), and major bleeding. Furthermore, efficacy was evaluated for these thromboprophylaxis regimens. Patients were compared in terms of gender, basal metabolic index (BMI), smoking history, diabetes mellitus (DM) and previous VTE. Patients were evaluated preoperatively for presence of DVT by Doppler ultrasonography (USG)

Patients were clinically and laboratory wise monitored for swelling, severe pain in the legs, shortness of breath, sudden decrease in lung oxygen saturation and decrease in hemoglobin (Hb) – hematocrit (Htc) levels in blood. D-Dimer in blood samples, Doppler USG, pulmonary CT angiography, Cranial MR angiography were done for patients with suspected DVT, PE (Figure-1).

Patients without clinical suspicion were checked with doppler USG twenty days after surgery. All patients with DVT and/or Pulmonary Embolism (PE), Cerebro-vascular thromboembolism (CVT) underwent antithrombotic treatment at the dose of treatment, were hospitalized and followed-up during this treatment and discharged after recovery. But, in two patients, drop in Htc was noticed, after abdominal CT and MRI exploration of retro peritoneal bleeding by general surgeon became necessary.

The groups were compared in terms of age, obesity diabetes and previous history of DVT. The rates of DVT, PE, and CVT were compared.

Statistical Analysis

SPSS 23.0 (IBM Corp., Armonk New York, USA) was used for statistical analysis. Parametric values were compared as mean, standard deviation (SD) and percentage. The difference between the groups was compared with Chi-square test and the significance was accepted as $p < 0.05$.

Table-1. The distribution of LMWH/rivaroxaban groups and risk factors

	Cohort (n=325)	LMWH group (n=225)	Rivaroxaban group (n=100)
Age, mean (SD)	63.2 (14.3)	61.4 (16.3)	62.4 (15.3)
Female/Male (R)	195/130 (1.5)	135/90 (1.5)	60/40 (1.5)
Obesity +/- (R)	210/115 (1.8)	142/83 (1.74)	68/32 (2.1)
Diabetes Mellitus +/- (R)	180/145 (1.33)	125/100 (1.28)	55/45 (1.27)
Smoke +/- (R)	150/175 (0.82)	105/120 (0.86)	45/55 (0.79)
Dvt history +/- (R)	20/325 (6.15%)	15/210 (7.14 %)	5/95 (5.26%)

Table-2. Comparison of the prophylaxis efficiency of LMWH and rivaroxaban.

	LMWH Group	Rivaroxaban Group	Total	χ^2	p
DVT	27/225 (12,0 %)	13/100 (13,0 %)	40/325 (12,3 %)	0,06	0,943
PE	11/225 (4,9 %)	4/100 (4,0 %)	15/325 (4,6 %)	0,12	0,949
CVT	4/225 (1,8 %)	1/100 (1,0 %)	5/325 (1,5 %)	0,28	0,974
SRPB	2/225 (0,9 %)	0 (0,0 %)	2/325 (0,6 %)	0,89	0,860
Total	44/225 (13,5 %)	18/100 (18,0 %)	62/325 (19,1 %)	0,11	0,860

DVT: Deep venous thrombosis, PE: Pulmonary embolism, CVT: Cerebrovascular embolism, SRPB: Spontaneous Retroperitoneal bleeding, LMWH (Low molecule weight heparine)

Results

The average age (SD) of the 325 patients included in the study was 63.2 ± 14.3 and the female/male ratio was 1.50 (195/130). 225 patients followed-up by LMWH and 100 patients followed-up by rivaroxaban against venous thromboembolism. DVT was not detected in any patient on preoperative Doppler USG. A total of 40 (12.3%), (27 LMWH group / 13 rivaroxaban group) patients had DVT at the lower extremity (Figure 1) and 15 (4.6%) (11 LMWH group / 4 rivaroxaban group) patients had PE (Figure 2) and surprisingly 5 (1.5 %) (4 LMWH group/ 1 rivaroxaban group) patients had cerebral emboli (Figure 3-4) at a level that did not cause mortality. Thus, 60 (16.9%) patients had thromboembolic disease despite the thromboprophylaxis. On the other hand, two patient had spontaneous retroperitoneal bleeding in LMWH group. The LMWH and rivaroxaban groups were compared in terms of average age (61.4/62.4), female/male ratio (1.5/1.5), occurrence of obesity (BMI > 30) (142/68), occurrence of diabetes (125/55), and previous DVT history (15/5), and there was a statistically insignificant difference between the groups ($p > 0.05$) (Table-1).

The use of LMWH and rivaroxaban in our cohort found DVT in 27/13, PE 11/4, Cerebrovascular embolism (CVT) 4/1, spontaneous retroperitoneal bleeding (SRPB) 2/0 respectively. Thromboprophylaxis was found to be similar in both prophylaxis regimes who underwent total knee replacement ($p > 0.05$) (Table-2). The DVT, PE and CVT developed in the first month of post-surgical period.

Fifteen patients who developed PE were examined. All patients with PE had a history of DVT in the past. Five patients with cerebrovascular thromboembolism (CVT) had also a history of DVT in the previous period. All PE cases recovered with medical therapy. The patients with CVT were all transient ischemic attacks and recovered in one month. The remaining eight patients who had DVT were

obese, diabetic and smokers. When the groups were compared according to these criteria, there was statistically insignificant difference between the groups ($p > 0.05$) (Table-2).

Surprisingly, in 2 (0,6 %) patients using enoxaparin sodium with long term regimen, retroperitoneal bleeding needing surgical treatment occurred. But this complication was not seen in the rivaroxaban group.

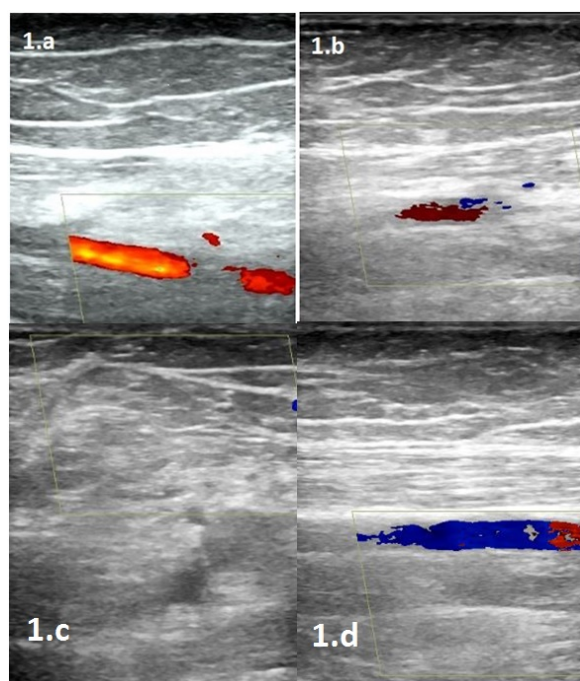


Figure-1. Pt.#126, 62 years old, female patient treated with total knee arthroplasty determined Deep Venous Thromboembolism in all deep venous sutructures in (a-d) Doppler USG of right leg while she was taking enoxaparin for thromboembolism prophylaxis at 22th day postoperatively.

Discussion

With the advancement in surgical techniques and despite widespread use of anticoagulants, VTE and PE are still the major cause of death after replacement surgeries. Mechanical and pharmacological agents are recommended against thromboembolism events after major orthopedic surgeries⁽¹¹⁾. It is crucial for orthopaedic surgeons to effectively use anticoagulants against DVT without causing any bleeding complications, which depends on

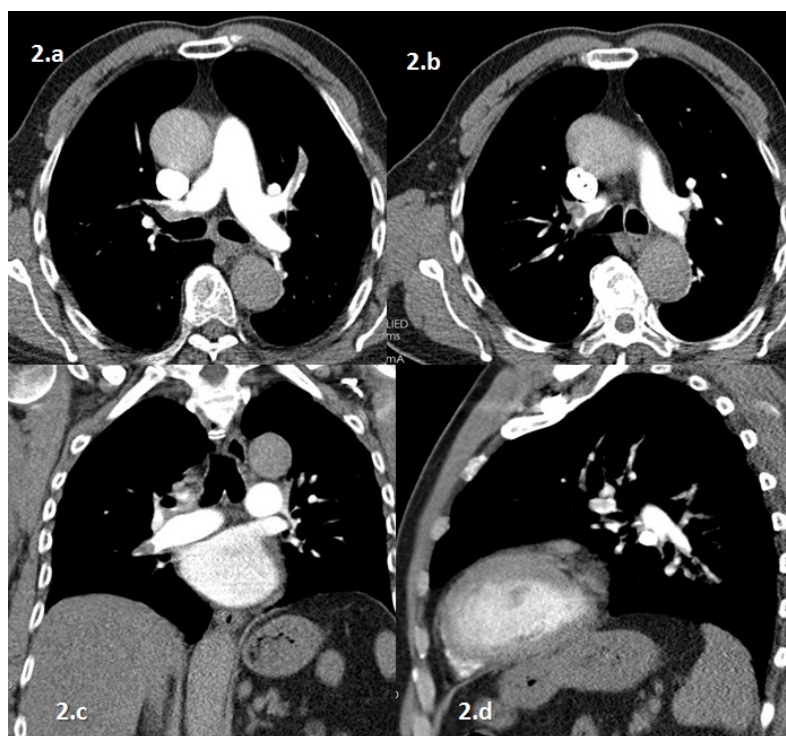


Figure-2. In Pt.#171, 68 years old, male patient treated with total knee arthroplasty, pulmonary embolism in left upper pulmonary segment artery and subtotal embolism both sides were stated in the pulmonary CT-angiography. Axial (a-b), coronal (c) and sagittal (d) CT views were seen in the figure.

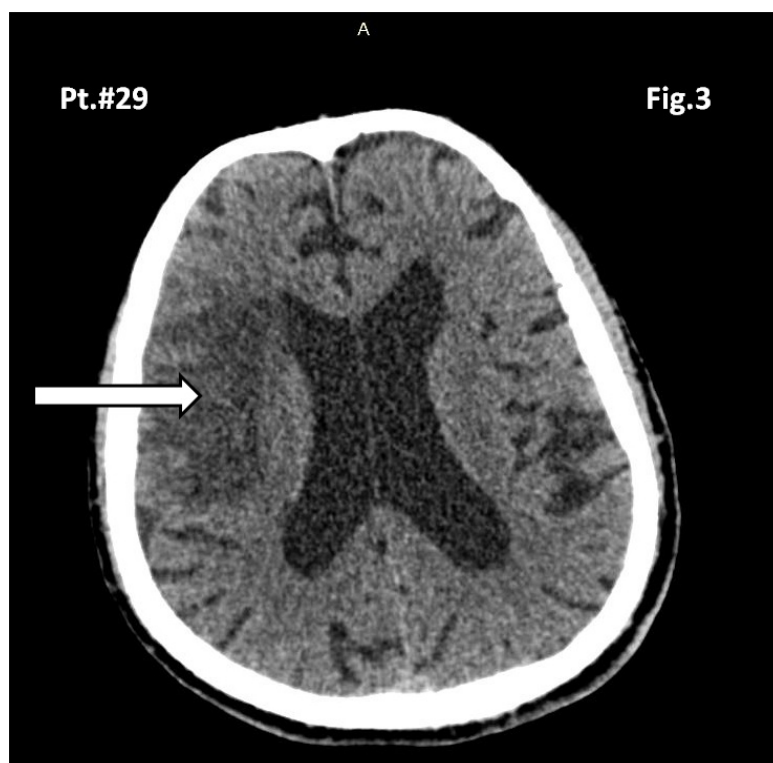


Figure-3. In Pt.#29, 65 years old, female patient treated with total knee arthroplasty, cerebrovascular embolism in right middle cerebral artery in cranial CT.

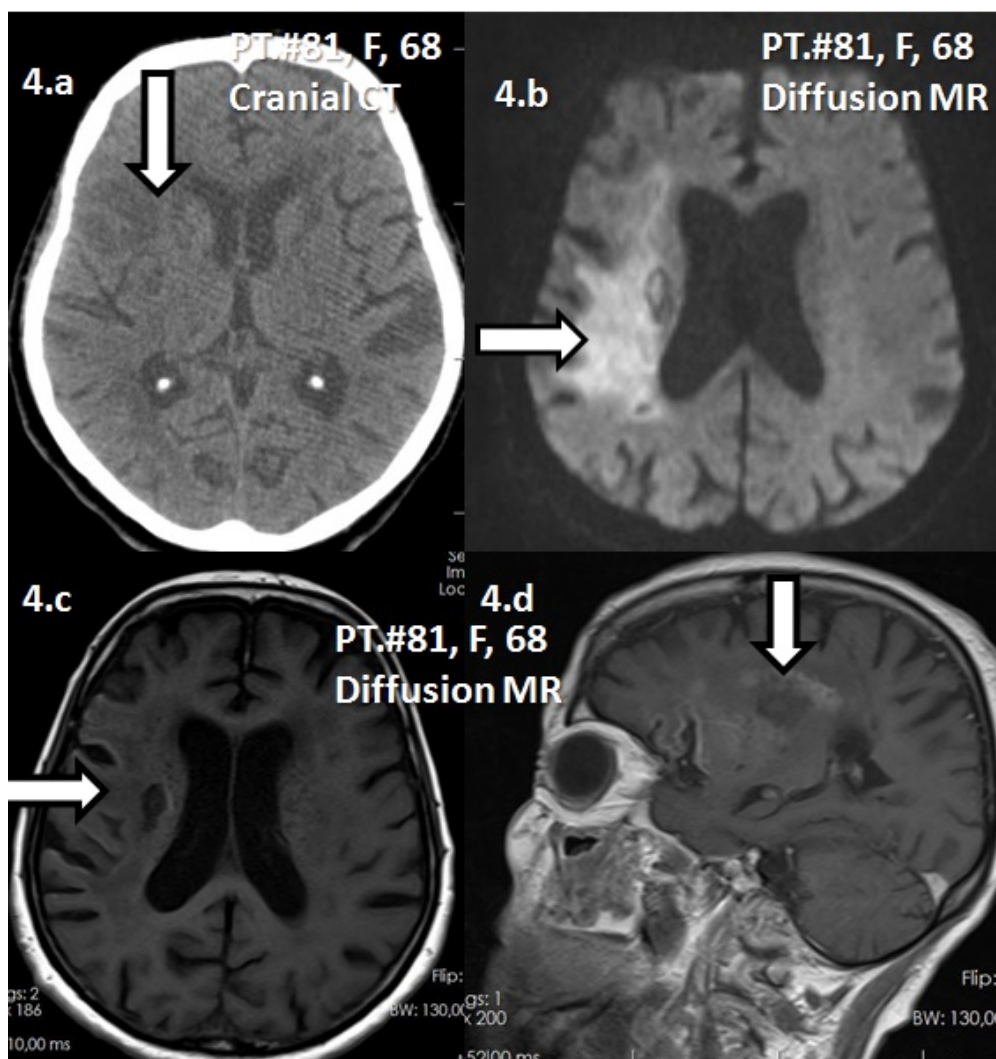


Figure-4. In Pt.#81, 68 years old, female patient treated with total knee arthroplasty, **(a)** cerebrovascular embolism in right middle serebral artery in cranial CT and **(b-d)** diffusion MR images.

the safety limits of the drug used in the prophylaxis treatment.

In a Canadian study, enoxaparin was found to be costly compared to rivaroxaban due to an excess use of thromboprophylaxis⁽¹⁶⁾. That study also found fewer symptomatic venous thrombotic events with rivaroxaban treatment compared to enoxaparin after replacement surgeries⁽¹⁶⁾. The proven efficacy and safety profile of enoxaparin makes it the most commonly used agent after replacement surgeries.⁽¹¹⁾ In a phase 3 study, enoxaparin, which is used commonly in Europe, and rivaroxaban were compared postoperatively

and rivaroxaban was found to be more effective in terms of VTE prevention and has the same safety level.⁽¹⁷⁾

In a prospective randomized study including 3,034 patients, Turpie et al.⁽¹⁸⁾ found that rivaroxaban was significantly superior in preventing venous thromboembolism compared to two doses of 0.3 mg enoxaparin per day, although there were more major and non-major bleeding complications. The bleeding complications were found statistically insignificant.¹⁸ A meta-analysis comparing rivaroxaban and enoxaparin also showed that rivaroxaban was more effective for prevention

of VTE after TKR and did not cause an increase in bleeding.⁽¹⁹⁾ Shahcheraghi et al.⁽²⁰⁾ followed-up 100 TKR patients with enoxaparin and warfarin post-surgically in southern Iran. They found no DVT, PE, major bleeding complications in their cohort. Our data showed more post-surgical complications, it may be related to high obesity, smoker, diabetes rates of our patients. Also, ethnicity could be related to these differences.

In contrast with these studies, a multicenter study including 2,762 British patients after knee and hip replacement, found a low DVT rate, but high wound complication with rivaroxaban.⁽²¹⁾

Secondary major hemorrhage to thromboprophylaxis was observed at a rate of 4-7.9 %.⁽²²⁾ Spontaneous retroperitoneal bleeding due to thromboprophylaxis had been reported about some vascular diseases.⁽²³⁾ Daliakopoulos et al.⁽²⁴⁾, and Lu et al.⁽²⁵⁾, and Dabney and Bastani et al.⁽²⁶⁾ also reported cases with kidney compression and abdominal compartment syndrome in secondary spontaneous retroperitoneal bleeding to thromboprophylaxis.

Contrary to some other studies, we did not find a significant difference between the groups in the postoperative period for both bleeding at the wound site and a decrease in blood hemoglobin-hematocrit values. This may be because we did not measure bleeding from drainage in our sample, and we did not find any significant difference in our groups in terms of leg rash and swelling. But we encountered retroperitoneal bleeding treated surgically in 2 (0.6 %) patients while the patients were taking enoxaparin sodium with long term regimen. All of our patients with PE and CVE had previously suffered from venous thromboembolism, unfortunately, we could not attain any supporting or opposing data in the literature. All of the DVT detected patients in our groups had one of the other risk factors such as diabetes mellitus, smoking or obesity. There are several studies about DVT risk factors^(5,27) however, we were unable to

determine the thromboprophylaxis protocols used among these risky patients.

A major limitation of our study was that randomization was not done, although it was a prospective study. Additionally, a group consisting of those who underwent total knee replacement and didn't use thromboprophylaxis was not established because this would be unethical. A prospective study by a single surgeon sheds light and therefore was thought to be important.

Conclusion

There was no difference between the use of rivaroxaban and enoxaparin for thromboembolism prophylaxis in total knee replacement surgery in terms of occurrence of venous thrombosis and pulmonary embolism. Long-term protocols may be useful in cases with smoking, diabetes and obesity. Patients with previous venous thromboembolism are at a high risk for pulmonary and cerebrovascular embolism. On the other hand, progressive Htc decreasing have to alert the surgeon for the spontaneous retroperitoneal bleeding in the patients taking enoxaparin for thromboembolism prophylaxis in total knee replacement surgery.

References

1. Brown TS, Huo MH. New anticoagulants for thromboprophylaxis after total knee arthroplasty. *Am J Orthop* 2013; 42: 424-429.
2. Geerts WH, Heit JA, Clagett GP, Pineo GF, Colwell CW, Anderson FA Jr, Wheeler HB. Prevention of venous thromboembolism. *Chest* 2001; 119: 132-175.
3. Nicolaides AN, Breddin HK, Fareed J, Goldhaber S, Haas S, Hull R, Kalodiki E, Myers K, Samama M, Sasahara A; Cardiovascular Disease Educational and Research Trust and the International Union of Angiology. Prevention of venous thromboembolism. International Consensus Statement. Guidelines compiled in accordance with the scientific evidence. *Int Angiol* 2001; 20(3): 1-37.
4. Warwick D, Friedman RJ, Agnelli G, Gil-Garay E, Johnson K, FitzGerald G, Turibio FM. Insufficient duration of venous thromboembolism prophylaxis after total hip or knee replacement when compared with the time course of thromboembolic events: findings from

the Global Orthopaedic Registry. *J Bone Joint Surg Br* 2007; 89: 799-807.

5. Selby R, Geerts WH. Venous thromboembolism: risk factors and prophylaxis. *Semin Respir Crit Care Med* 2000; 21: 493-501.

6. Beyer J, Schellong S. Deep vein thrombosis: Current diagnostic strategy. *Eur J Intern Med* 2005; 16: 238-246.

7. Goodacre S, Sampson F, Thomas S, van Beek E, Sutton A. Systematic review and meta-analysis of the diagnostic accuracy of ultrasonography for deep vein thrombosis. *BMC Med Imaging* 2005; 3: 2-13.

8. Thomas SM, Goodacre SW, Sampson FC, Van Beek EJ. Diagnostic value of CT for deep vein thrombosis: results of a systematic review and meta-analysis. *Clin Radiol* 2008; 63: 299-304.

9. Cohen AT, Tapson VF, Bergmann JF, Goldhaber SZ, Kakkar AK, Deslandes B, Huang W, Zayaruzny M, Emery L, Anderson FA, Endorse investigators. Venous thromboembolism risk and prophylaxis in the acute hospital care setting (ENDORSE study): a multinational cross-sectional study. *Lancet* 2008; 2: 387-394.

10. Lieberman JR, Hsu WK. Prevention of venous thromboembolic disease after total hip and knee arthroplasty. *J Bone Joint Surg Am* 2005; 87: 2097-2112.

11. Falck-Ytter Y, Francis CW, Johanson NA, Curley C, Dahl OE, Schulman S, Ortel TL, Pauker SG, Colwell CW Jr. Prevention of VTE in orthopedic surgery patients: Antithrombotic Therapy and Prevention of Thrombosis, 9th ed: American College of Chest Physicians Evidence-Based Clinical Practice Guidelines. *Chest* 2012; 141: 278-325.

12. Fassiadis N. Rivaroxaban: direct factor Xa inhibition to treat acute deep vein thrombosis. *Br J Hosp Med*. 2011; 72: 486-487.

13. Chen T, Lam S. Rivaroxaban: an oral direct factor Xa inhibitor for the prevention of thromboembolism. *Cardiol Rev* 2009; 17: 192-197.

14. Lieberman JR, Pensak MJ. Prevention of venous thromboembolic disease after total hip and knee arthroplasty. *J Bone Joint Surg Am* 2013; 95: 1801-1811.

15. Mont MA, Jacobs JJ. AAOS clinical practice guideline: preventing venous thromboembolic disease in patients undergoing elective hip and knee arthroplasty. *J Am Acad Orthop Surg* 2011; 19: 777-778.

16. Diamantopoulos A, Lees M, Wells PS, Forster F, Ananthapavan J, McDonald H. Cost-effectiveness of rivaroxaban versus enoxaparin for the prevention of postsurgical venous thromboembolism in Canada. *Thromb Haemost* 2010; 104: 760-770.

17. Nieto JA, Espada NG, Merino, RG, Gonzalez TC. Dabigatran, rivaroxaban and apixaban versus enoxaparin for thromboprophylaxis after total knee or hip arthroplasty: pool-analysis of phase III randomized clinical trials. *Thromb Res* 2012; 130: 183-191.

18. Turpie AG, Lassen MR, Davidson BL, Bauer KA, Gent M, Kwong LM, Cushner FD, Lotke PA, Berkowitz SD, Bandel TJ, Benson A, Misselwitz F, Fisher WD; RECORD4 Investigators. Rivaroxaban versus enoxaparin for thromboprophylaxis after total knee arthroplasty (RECORD4): a randomised trial. *Lancet* 2009; 373: 1673-1680.

19. Huang HF, Li SS, Yang XT, Xie Q, Tian XB. Rivaroxaban versus enoxaparin for the prevention of venous thromboembolism after total knee arthroplasty: A meta-analysis. *Medicine* 2018; 97(48):1-9.

20. Shahcheraghi GH, Javid M, Arasteh MM. Thromboembolic disease after knee arthroplasty is rare in southern Iran. *J Orthop* 2014; 31(2):86-91.

21. Jameson SS, Rymaszewska M, Hui AC, James P, Serrano-Pedraza I, Muller SD. Wound complications following rivaroxaban administration: a multicenter comparison with low-molecular-weight heparins for thromboprophylaxis in lower limb arthroplasty. *J Bone Joint Surg Am* 2012; 94-A: 1554-1558.

22. Sachs RA, Smith JH, Kuney M, Paxton L. Does anticoagulation do more harm than good?: A comparison of patients treated without prophylaxis and patients treated with low-dose warfarin after total knee arthroplasty. *J Arthroplasty* 2003; 18: 389-395.

23. Sunga KL, Bellolio MF, Gilmore RM, Cabrera D. Spontaneous retroperitoneal hematoma: etiology, characteristics, management, and outcome. *J Emergency Med* 2012; 43(2): e157-e161.

24. Daliakopoulos SI, Bairaktaris A, Papadimitriou D, Pappas P. Gigantic retroperitoneal hematoma as a complication of anticoagulation therapy with heparin in therapeutic doses: a case report. *J Med Case Rep*. 2008; 2(1): 162. 10.1186/1752-1947-2-162.

25. Lu HY, Wei W, Chen QW, Meng QG, Hu GH, Yi XL, Bai XZ. A rare life-threatening disease: Unilateral kidney compressed by huge chronic spontaneous retroperitoneal hemorrhage. *Therapeutics Clin Risk Manag* 2018; 14: 489-492.

26. Dabney A and B. Bastani B. Enoxaparin-associated severe retroperitoneal bleeding and abdominal compartment syndrome: A report of two cases. *Inten Care Med* 2001; 27(12): 1954-1957.

27. Kunutsor SK, Beswick AD, Whitehouse MR, Blom AW. Systematic review of risk prediction scores for venous thromboembolism following joint replacement. *Thromb Res* 2018; 168: 148-155.