

Atypical Femoral Fractures (Short-term Treatment Outcome)

Abstract

Background: The prevalence of atypical femoral fractures in the elderly population is increasing worldwide, including in Iran. Left untreated, these fractures can lead to disability and reduced quality of life for such patients.

Methods: This case-series study was conducted on one-hospital experience on patients with atypical femoral fractures who underwent surgery from 2013 to 2020. Demographic and clinical information, complications, and postoperative walking ability, as well as modified Harris Hip Score (HHS) and Numeric Rating Scale (NRS) scores, were collected at one month and one year after surgery.

Results: Among the 30 participants in this study, 24 (80%) were female. The mean age of the patients was 68.66 ± 11.03 years. Of the patients, 14 (46.6%) underwent plate fixation, 8 (26.7%) intramedullary nailing, and 26.7% underwent PFNA surgery. After surgery, 6 patients (20%) regained full ability to walk, 20 were able to walk with a cane or walker, and 4 could not walk. The NRS score of patients decreased by 2.80 ± 1.20 points after surgery, while the modified HHS score increased by 9.13 ± 22.56 (P value >0.05). After surgery, 4 (13.3%) of patients developed an infection. The type of surgery did not significantly affect patients' hip function or pain after surgery (P value >0.05).

Conclusion: The rate of complications and postoperative infections in atypical femoral fractures is higher than typical femoral fractures, and the postoperative mobility and patients' satisfaction are lower.

Keywords: Femoral fractures, Geriatrics, Outcome assessment, Fracture fixation.

Received: 4 months before printing; Accepted: 3 months before printing

Ali Yeganeh, MD¹; Amir Ebrahimzadeh Babaki, MD¹; Sepideh Najafi Torbehbar, MD¹

¹Department of Orthopaedic,
School of Medicine, Iran
University of Medical Science,
Tehran, Iran.

Corresponding Author:
A Ebrahimzadeh Babaki; MD
Email Address:
amirebrahimzadeh13@
gmail.com

Introduction

We are stepping into a society with a significant ageing population, and it is known that one out of six women will suffer from osteoporotic fracture at least once during their lifetime⁽¹⁾. Bisphosphonates (BP) are the most commonly prescribed type of medication for the treatment of osteoporosis (OP). Treatment with bisphosphonates, however, is not without adverse effects, because bisphosphonates act by inhibiting osteoclast function and inducing osteoclast apoptosis. There is a substantial concern regarding the potential side effects related to severe suppression of the bone turnover rate⁽²⁾.

Atypical femoral fracture (AFF), one of the potential complications of prolonged BP therapy for the treatment of OP, has raised reasonable concerns in recent years⁽³⁾. Atypical femoral fractures have several clinical characteristics that distinguish them from ordinary femoral fractures: First, the fracture line must extend from just distal to the lesser trochanter to just proximal to the supracondylar flare. Second, there is no history of trauma, or the injury occurs due to minimal force (e.g., falling from standing height). Lastly, there are a number of representative radiographic findings such as minimal or no comminution with medial spike, transverse or short oblique fracture orientation, localized thickening of the lateral cortex⁽⁴⁾.

The management of atypical femoral fractures requires a specific protocol that includes both medical and surgical treatment.

Medical treatment includes discontinuation of bisphosphate or other potent antiresorptive drugs, daily prescription of calcium and vitamin D⁽⁵⁾ and use of Teriparatide (TPTD), a recombinant form of parathyroid hormone (PTH)⁽⁶⁾. Cephalomedullary nailing is the preferred method for surgical fixation of AFF. However, plate fixation and other methods may come into consideration depending on type of fracture and fracture location⁽⁷⁾.

Most studies have reported high complications rate including infection, delayed healing, implant failure, and revision surgery. These outcomes in previous reports have been reported based on the mixture of surgical methods including mainly intramedullary (IM) and extramedullary devices^(8, 9, 10).

The purpose of this study was to evaluate surgical outcomes in patients with AFFs who took BP therapy and to investigate the relationship between these outcomes and patients' characteristics.

Methods

In this case-series study, we examined patients diagnosed with atypical femoral fractures who underwent surgery at Rasoule Akram Hospital in Tehran, Iran, from January 2013 to March 2020. Ethical approval was obtained from the Ethics Committee of Iran University of Medical Sciences, and written informed consent was obtained from all patients.

All patients had a history of taking bisphosphonates (BP), and radiographic findings were consistent with the characteristics of atypical femoral fractures, including short oblique or transverse fractures located anywhere in the femur, from the distal portion of the lesser trochanter to the proximal portion of the supracondylar prominence. These fractures were not comminuted and resulted from mild trauma. Patients had at least one-year follow-up. Patients who did not meet all of these conditions were excluded from the study. Patients with congenital diseases, thyroid disorders, and calcium and phosphorus absorption disorders that could affect the

surgical outcome were also excluded. Patients' demographics, including age and sex, information regarding medication history, radiographic X-rays, and the type of performed surgery, were extracted from hospital records.

For all patients, BP had been discontinued after the diagnosis of atypical fracture, and calcium and Vitamin D supplementation were prescribed. Surgical interventions were carried out using advantage of functions: intramedullary nail, Proximal Femoral Nail Antirotation (PFNA) or plate fixation, based on the surgeon's judgment (Figure 1, 2, and 3). Clinical evaluation included assessing postoperative complications, such as wound problems, anesthesia-related issues, and radiological evaluation through follow-up X-rays taken immediately post-operation, and at one, six months, and one-year post-operation. Patient follow-up was conducted through phone calls and review of data entered in their files during clinic visits.

Non-union, delayed union, and implant failure were investigated using radiographic images. Non-union was defined as a fractured bone that has not fully healed nine months after injury, while delayed union was defined as the absence of evidence of bone union at six months after surgery.

Modified HHS (Harris Hip Scale) score⁽¹¹⁾ and NRS (Numerical Rating Scale) pain score⁽¹²⁾ both at one month and one year after surgery, as well as patients' walking ability at one year after the operation were evaluated through the follow-up phone calls to the patients and studying patients' clinic records. The Modified HHS score is a functional assessment scale for the hip that assesses pain, gait, and functional activities⁽¹¹⁾. The NRS pain score is employed to evaluate pain, indicating the proportional level of pain on a scale from zero (no pain) to 10 (worst possible pain), as reported by the patients⁽¹²⁾.

Patients were also categorized into four groups based on their walking ability: those who could walk without assistance, those who could walk with a cane, those who could walk with a walker, and those who were unable to walk.

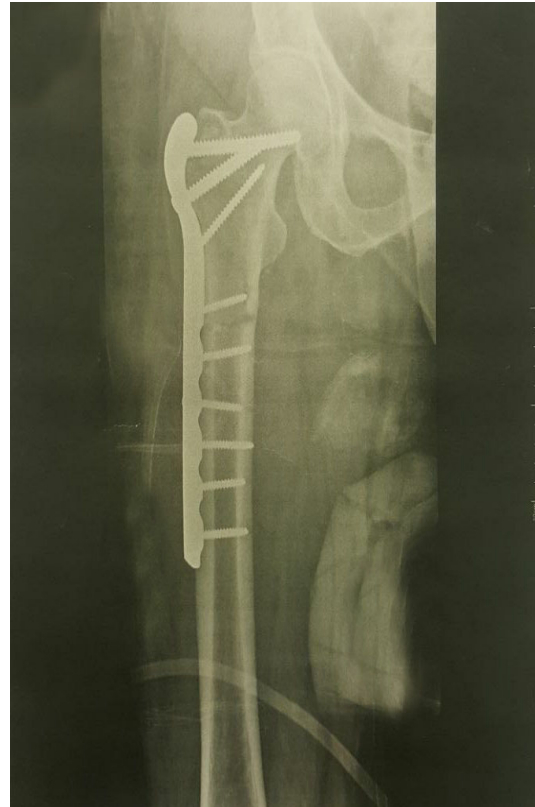
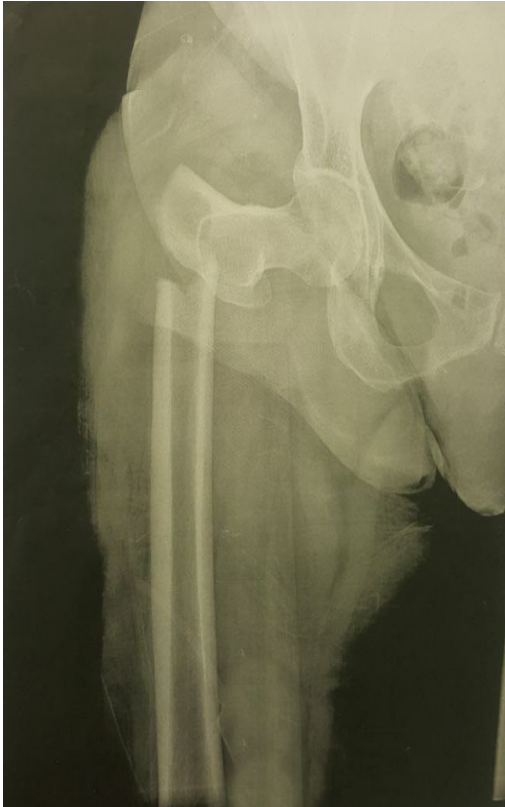
Figure 1: A 74-year-old female with a two-year history of taking bisphosphonates presented after a low energy fall resulting in a right atypical femoral fracture treated with a plate

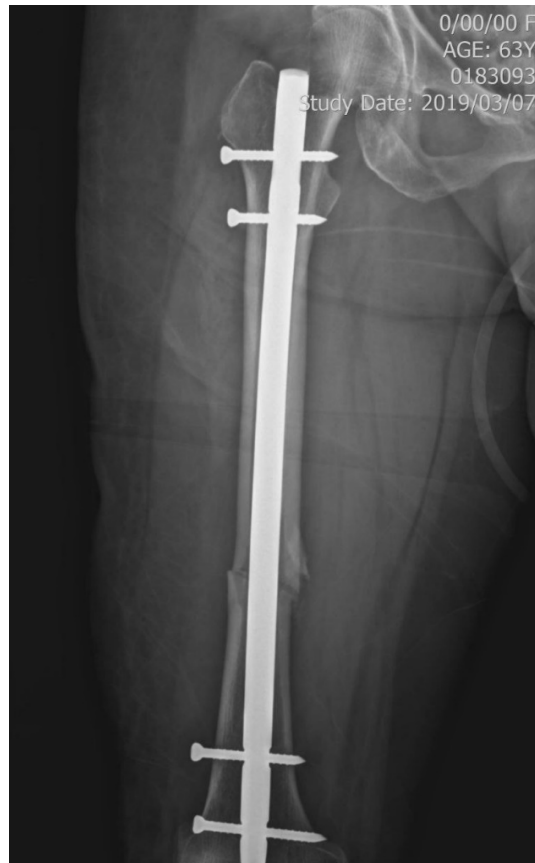
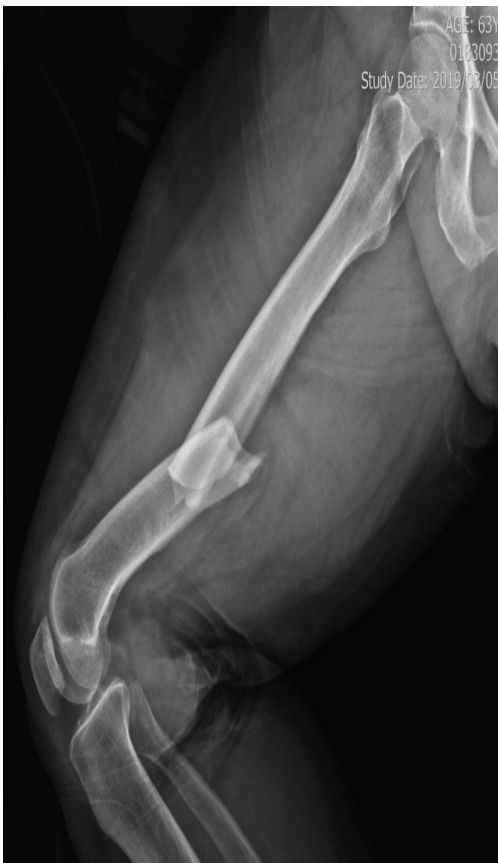

Figure 2: A 63-year-old female with a one-year history of taking bisphosphonates presented after a low energy trauma resulting in a right atypical femoral fracture treated with an intramedullary nail

Following data collection, the data were entered into SPSS version 26 software and analyzed. Quantitative variables were reported as mean and standard deviation (Mean \pm SD), and categorical qualitative variables as percentages. Independent T-Test and Mann-Whitney U Test were used to compare quantitative variables, while Pearson and Spearman Correlation were used to assess relationships between quantitative variables. Chi-Square Test and Fisher's Exact Test were employed to examine relationships between qualitative variables. A significance level of less than 0.05 was considered statistically significant.

Results

A total of 30 patients who underwent surgery for atypical femoral fractures were included in the study. The majority of the patients were women (80%, n=24) with a mean age of 68.7 ± 11.0 (45-84) years. With 16 (53.3%) occurring on left femur (Table 1).

Based on the Kolmogorov-Smirnov test, the data distribution was found to be normal. The number of men with AFF was significantly lower than that of women (p value=0.020).

Regarding surgical methods, 14 patients (46.6%) underwent plate surgery, while eight patients (26.7%) underwent intramedullary nailing (IMN) surgery, and another eight patients (26.7%) underwent PFNA surgery.

At one year after the operation, the patients' walking ability was assessed. Six patients (20%) regained their full ability to walk after surgery, 20 patients (66.7%) could walk with a cane or walker, while 4 patients (13.3%) were unable to walk.

The union of AFF was evaluated, revealing that 20 patients (66.7%) had union, two (6.7%) had malunion, and eight patients (26.6%) had non-union in their radiographs.

In the evaluation of complications, four patients (13.3%) experienced an infection after surgery. These four patients exhibited worsened scores on the modified HHS and NRS both one month, and also one year after surgery, and they all lost the ability to walk.

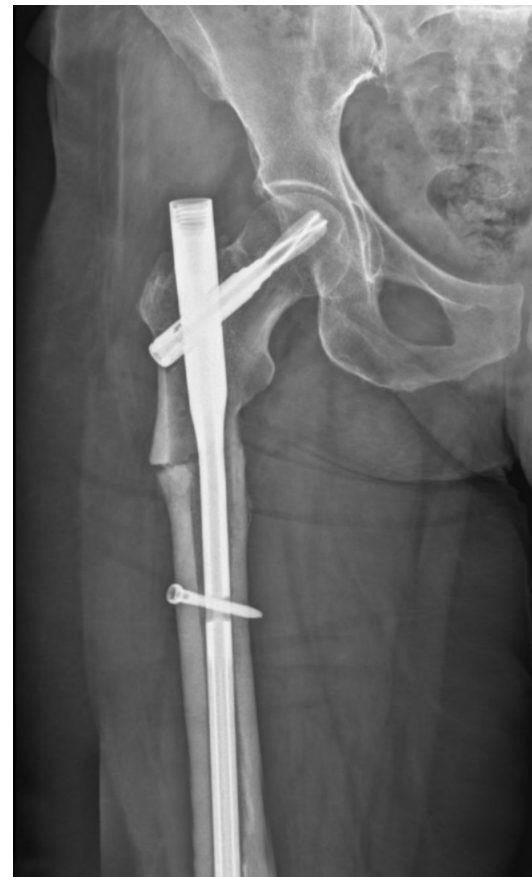
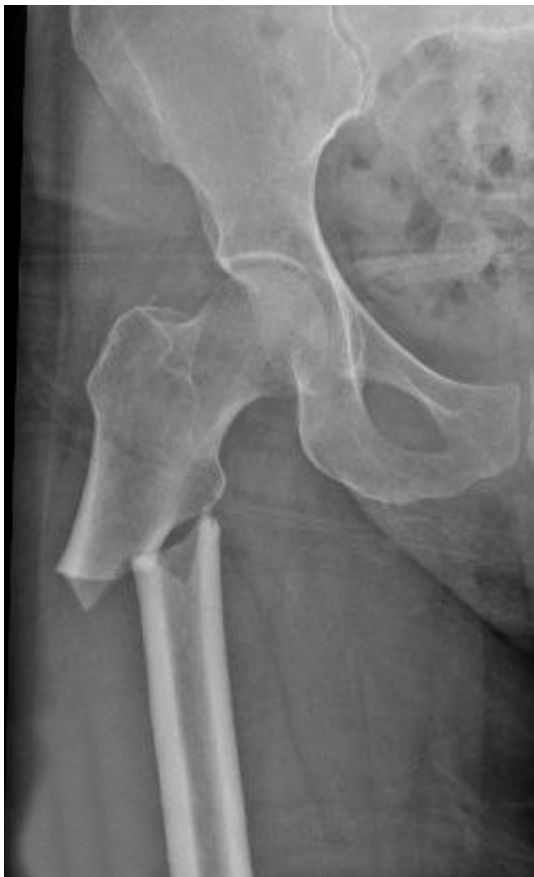
Figure 3: A 72-year-old female with a three-year history of taking bisphosphonates presented after a low energy fall resulting in a right atypical femoral fracture treated with a Proximal Femoral Nail Antirotation (PFNA)

These four patients had initially undergone plate fixation and subsequently required reoperation consisting of debridement, irrigation, Replating and bone grafting -in all of the 4 cases. Plate removal + Debridement + Irrigation + Refixation with plate + Bone graft were performed for all these 4 patients.

The Modified HHS score at one month after surgery was recorded as 38.66 ± 12.94 , and at one year after surgery, it was 47.80 ± 30.27 . While there was an improvement in the hip function one year after surgery compared to one month after surgery (indicated by an increase in the modified HHS), this difference was not statistically significant ($P \text{ value} > 0.05$). The NRS score at one month after surgery was 6.60 ± 1.54 , and 5.40 ± 3.33 one year after

surgery. Although there was a reduction in pain experienced by patients one year after surgery compared to one month after surgery (indicated by a decrease in NRS scores), this reduction was not statistically significant ($P \text{ value} > 0.05$) (Table 2).

The changes in modified HHS scores calculated between one month and one year after surgery were lower in older patients, while NRS score changes calculated at the same intervals increased with age. However, none of these correlations reached statistical significance ($P \text{ value} > 0.05$).

The type of surgery also did not have a statistically significant impact on hip function pain after surgery ($P \text{ value} > 0.05$) (Table 3).

Table 1: Baseline demographic characteristics of patients			
Variables	Results		
Gender	Men: 20% (n=6)	Women: 80% (n=24)	
Age	Mean: 68.7 ± 11.0 (Min:45, Max:84)		
Side of fracture	Right: 40% (n=12)	Left: 53.3% (n=16)	Both: 6.7% (n=2)

Table 2: Evaluating the statistical differences of modified HHS and NRS between one month and one year after surgery				
Scales	One month after surgery	One year after surgery	Difference	P Value
Modified HHS	38.66 ± 12.94	47.80 ± 30.27	22.56 ± 9.13	0.139
NRS	6.60 ± 1.54	5.40 ± 3.33	2.80 ± 1.20	0.120

Table 3: Correlation between patients' age and type of surgery with modified HHS and NRS score changes					
Changes in scales	Age		Type of surgery		
	Correlation Coefficient	P Value	Nailing (Mean±SD)	Plate (Mean±SD)	P Value
Modified HHS	-0.491	0.063	22.16 ± 5.50	24.01 ± 13.28	0.525
NRS	0.424	0.115	2.67 ± 0.5	2.94 ± 2	0.320

Discussion

The incidence of atypical femoral fractures (AFFs) continues to increase worldwide. However, there remains a scarcity of studies examining the complications associated with AFFs and their predictive factors.

We, therefore, tried to investigate the outcomes and complications of treating this condition through a short-term follow-up study involving 30 patients.

Most of the patients in our AFF study were women (80%), with an average age of 68.7 ± 11.0 years. In recent studies, the number of affected women was more than men^(9, 10, 13, 14). However, most studies are limited to postmenopausal white women, many of whom have used medications such as bisphosphonates⁽¹⁵⁾.

Several studies have reported a high rate of complications (delayed union, non-union, fixation failure, reoperation after surgical treatment) associated with AFFs, similar to our findings. For instance in a study conducted by Bogdan et al., which included 179 patients with AFF who underwent surgery, 29 patients experienced higher complication such as infection, delayed healing compared to typical femoral fractures; and also a higher rate of non-union, with 12% requiring reoperation, on average, at 11 months post-surgery⁽¹⁰⁾. Schlicher's study revealed that patients with AFFs require re-surgery at a rate four times higher than patients with common femoral shaft fractures, with the primary reason being fragility around the implant⁽¹⁶⁾. Kyung-Jae Lee et al. reported 37% delayed union in their study⁽⁹⁾. Additionally, Teo et al. reported implant failure in 23% of cases, leading to revision surgery in 33% of patients⁽¹⁷⁾. Koh et al. found that revision surgery for non-union or implant failure was necessary in 12.6% of AFFs cases⁽¹⁸⁾. In our study, the infection rate was 13.3%, malunion affected 6.7% patients, and non-union occurred in 26.6% of patients. In the present study, the type of surgery (nailing vs. plating) did not have a statistically significant influence on the hip function or pain (P -value>0.05). However, it's noteworthy that all four patients who developed

infections and required reoperation had undergone plating procedures. In the study by Teo et al., the rate of implant failure and revision rate were considerably higher in the extramedullary device group (29% and 38%, respectively) compared to the intramedullary device group (11.1% and 22.2%, respectively)⁽¹⁷⁾. Similarly, Koh et al. reported a higher percentage of fractures treated with plate fixation (31.3%) requiring revision surgery compared to those treated with intramedullary nailing (12.9%)⁽¹⁸⁾. In a systematic review study conducted by Ebrahimipour et al., 6 out of 38 cases with extramedullary fixation devices required revision surgery (15.7%), whereas only 20 out of 310 cases with intramedullary devices needed revision (6.45%)⁽¹⁹⁾.

It seems that employing a reconstruction or/with cephalomedullary nail that covers the full length of the femur yields superior outcomes compared to using an extramedullary device. However, plating may be a viable option in cases where nailing is challenging, such as in the presence of narrow medullary canal, existing metal devices, or when addressing femoral bowing.

In the study by Mishra et al., the Modified Hip Harris Score improved to 66.12 in three month's post-op and reached 80.53 at one year post-op, 75% of patients in their study regained normal walking abilities after AFF⁽²⁰⁾. Yoon et al. reported a significant improvement in HHS scores, from 64.9 (95% CI, 56.4–67.4) at discharge to 76.3 (95% CI, 70.2–82.4) at the six-month follow-up ($p < 0.001$)⁽²¹⁾. Kyung-Jae Lee found that thirty seven patients (84.1%) out of 44 in their study achieved their pre-fracture ambulatory function⁽⁹⁾.

In the present study, improvement, in hip function did not reach statistical significance (P value>0.05). Additionally, although there was a reduction in pain levels after surgery, this reduction was not statistically significant (P value>0.05). Only six patients (20%) regained the ability to walk without assistance, while 20 patients (66.7%) required the aid of a cane or walker.

We are aware that this study has several limitations. The retrospective design of the study and short follow-ups are its inherent limitations. This research can serve as a valuable resource for orthopaedic surgeons managing AFF cases. Nevertheless, prospective randomized trials with a larger sample size and longer follow-ups are needed to gain a more comprehensive understanding of this rare fracture type.

Conclusion

In general, the rate of complications such as infection and non-union in AFF surgery is higher than usual and the activity level and patients' satisfaction is lower than usual. Surgery in patients with AFF requires more preparations, more precision of the surgeon, more care of the patient and the necessary training for them and needs closer attention than typical femoral fractures.

References

1. Cummings SR, Black DM, Rubin SM. Lifetime risks of hip, Colles', or vertebral fracture and coronary heart disease among white postmenopausal women *Arch Intern Med*. 1989;149(11):2445-8. PMID: 2818106.
2. Unnanuntana A, Saleh A, Mensah KA, Kleimeyer JP, Lane JM. Atypical femoral fractures: what do we know about them?: AAOS Exhibit Selection. *J Bone Joint Surg Am*. 2013;95(2):e8 1-13. doi: 10.2106/JBJS.L.00568. PMID: 23324969.
3. Dell RM, Adams AL, Greene SF, Funahashi TT, Silverman SL, Eisemon EO, et al. Incidence of atypical nontraumatic diaphyseal fractures of the femur. *J Bone Miner Res*. 2012;27(12):2544-50. doi: 10.1002/jbmr.1719. PMID: 22836783.
4. Lee KJ, Min BW. Surgical treatment of the atypical femoral fracture: overcoming femoral bowing. *Hip Pelvis*. 2018;30(4):202-209. doi: 10.5371/hp.2018.30.4.202. PMID: 30534538, PMID: PMC6284073.
5. Shane E, Burr D, Abrahamsen B, Adler RA, Brown TD, Cheung AM, et al. Atypical subtrochanteric and diaphyseal femoral fractures: second report of a task force of the American Society for Bone and Mineral Research. *J Bone Miner Res*. 2014;29(1):1-23. doi: 10.1002/jbmr.1998. PMID: 23712442.
6. Im GI, Lee SH. Effect of teriparatide on healing of atypical femoral fractures: a systemic review. *J Bone Metab*. 2015;22(4):183-9. doi: 10.11005/jbm.2015.22.4.183. PMID: 26713309, PMID: PMC4691592.
7. Larsen MS, Schmal H. The enigma of atypical femoral fractures: A summary of current knowledge. *EFORT Open Rev*. 2018;3(9):494-500. doi: 10.1302/2058-5241.3.170070. PMID: 30305933, PMID: PMC6174857.
8. Prasarn ML, Ahn J, Helfet DL, Lane JM, Lorch DG. Bisphosphonate-associated femur fractures have high complication rates with operative fixation. *Clin Orthop Relat Res*. 2012;470(8):2295-301. DOI: 10.1007/s11999-012-2412-6. PMID: 22669553, PMID: PMC3392377.
9. Lee KJ, Yoo JJ, Oh KJ, Yoo JH, Rhyu KH, Nam KW, et al. Surgical outcome of intramedullary nailing in patients with complete atypical femoral fracture: a multicenter retrospective study. *Injury*. 2017;48(4):941-945. doi: 10.1016/j.injury.2017.02.036. PMID: 28274470.
10. Bogdan Y, 3rd PT, Einhorn TA, Guy P, Leveille L, Robinson J, et al. (2016). Healing time and complications in operatively treated atypical femur fractures associated with bisphosphonate use: a multicenter retrospective cohort. *J Orthop Trauma*. 2016;30(4):177-81. doi: 10.1097/BOT.0000000000000516. PMID: 26709814.
11. Vishwanathan K, Akbari K, Patel AJ. Is the modified Harris hip score valid and responsive instrument for outcome assessment in the Indian population with pertrochanteric fractures? *J Orthop*. 2018;15(1):40-46. doi: 10.1016/j.jor.2017.12.001. PMID: 29326497, PMID: PMC5760250.
12. Haefeli M, Elfering A. Pain assessment. *Eur Spine J*. 2006;15 Suppl 1(Suppl 1):S17-24. doi: 10.1007/s00586-005-1044-x. PMID: 16320034, PMID: PMC3454549.
13. Marcano A, Taormina D, Egol KA, Peck V, Tejwani NC. Are race and sex associated with the occurrence of atypical femoral fractures? *Clin Orthop Relat Res*. 2014;472(3):1020-7. DOI: 10.1007/s11999-013-3352-5. PMID: 24166075, PMID: PMC3916602.
14. Rudran B, Super J, Jandoo R, Babu V, Nathan S, Ibrahim E, et al. Current concepts in the management of bisphosphonate associated atypical femoral fractures. *World J Orthop*. 2021;12(9):660-671. doi: 10.5312/wjo.v12.i9.660. PMID: 34631450, PMID: PMC8472443.

15. Becker C, Crow S, Toman J, Lipton C, McMahon DJ, Macaulay W, et al. Characteristics of elderly patients admitted to an urban tertiary care hospital with osteoporotic fractures: correlations with risk factors, fracture type, gender and ethnicity. *Ost Int.* 2006;17:410-416.
16. Schilcher J. High revision rate but good healing capacity of atypical femoral fractures. A comparison with common shaft fractures. *Injury.* 2015;46(12):2468-73. doi: 10.1016/j.injury.2015.09.031. PMID: 26477344.
17. Teo BJX, Koh JSB, Goh SK, Png MA, Chua DTC, Howe TS. Post-operative outcomes of atypical femoral subtrochanteric fracture in patients on bisphosphonate therapy. *Bone Joint J.* 2014;96-B(5):658-64. doi: 10.1302/0301-620X.96B5.32887. PMID: 24788502.
18. Koh A, Guerado E, Giannoudis PV. Atypical femoral fractures related to bisphosphonate treatment: issues and controversies related to their surgical management. *Bone Joint J.* 2017;99-B(3):295-302. DOI: 10.1302/0301-620X.99B3.BJJ-2016-0276.R2. PMID: 28249967.
19. Ebrahimpour A, Sadighi M, Hoveidaei AH, Chehrassan M, Minaei R, Vahedi H, et al. Surgical treatment for bisphosphonate-related atypical femoral fracture: A systematic review. *Arch Bone Jt Surg.* 2021;9(3):283-296. doi: 10.22038/abjs.2020.52698.2608. PMID: 34239955, PMCID: PMC8221447.
20. Mishra D, Mohanty T, Nanda SN, Gulia A, Konchada S, Samant S, et al. Functional and Radiological Outcome in Atypical Subtrochanteric Femur Fracture After Surgical Fixation: A Retrospective Observational Study. *Cureus.* 2022;14(9):e29201. doi: 10.7759/cureus.29201. PMID: 36258929, PMCID: PMC9569151.
21. Yoon JY, Kim JW. Treatment of proximal femur fracture with a newly designed nail: trochanteric fixation nail-advanced (TFNA). *J Korean Fract Soc.* 2020;33(4):189-195. DOI:10.12671/jkfs.2020.33.4.189.