

## Evaluating the effect of intra-articular injection for bone marrow mesenchymal stem cells in repairing damaged cartilage of rat knee joint

### Abstract

**Background:** Damage in cartilage tissue is one of the global challenges and affects a large percentage of people. Trauma or age-related degenerative disease is the main cause of osteoarthritis. The aim of this study was to evaluate the effect of intra-articular injection for bone marrow mesenchymal stem cells and the resulting secretions in repairing the damaged cartilage of the rat knee joint.

**Methods:** 30 male rats that weights approximately 200 to 250 g were randomly divided into five groups of 6 rats, including healthy group (receiving physiological serum), osteoarthritis group (monosodium iodoacetate injection), mesenchymal group, mesenchymal group + receiving the same volume of cell secretions + culture medium and culture medium injection group. Four weeks later, the rats have been killed and the hip joint examined by both macroscopic and microscopic methods.

**Results:** The results showed that the injection of  $2.5 \times 10^5$  cells per ml had a good effect on the repairing of cartilaginous lesions caused by the monosodium iodoacetate injection. Histological studies showed that fibrillation rate, the presence of small gaps and deep gaps ( $P < 0.05$ ) decreased in the mesenchymal treatment group. The level of proteoglycans in mesenchymal treatment group increased significantly ( $P < 0.05$ ). Also, in the treatment group with mesenchymal secretions and culture medium, changes were observed in repairing the damaged cartilage, which was not significantly different from the osteoarthritis group.

**Conclusion:** In this study, the restorative effect has been confirmed for bone marrow mesenchymal stem cells and their secretions in improving histopathological lesions of rat articular cartilage.

**Keywords:** Osteoarthritis, Articular cartilage, Mesenchymal stem cell, Bone marrow

**Received:** 2.5 months before printing; **Accepted:** 1 month before printing

Dr. Davood Asgari

### Introduction

In osteoarthritis, articular cartilage is damaged and demolished by wear and scratches. As a result, the bone near the joint has been changed and small bumps called osteophytes formed around the joint <sup>(1)</sup>. The knee joint is more vulnerable to injury than other joints due to the constant and high pressures that are applied to it in daily activities, and the cartilage lacks nerves and does not feel pain during the injury, which causes more damage <sup>(2)</sup>. Osteoarthritis has many symptoms, however, its three most common symptoms includes joint dryness at rest, decreased flexibility, and pain <sup>(3)</sup>. It is the second most common complaint of outpatients and varies by gender and race <sup>(4)</sup>. Its prevalence is higher in blacks and Chinese people than whites due to high physical activity and genetic background <sup>(5)</sup>. It is more common in men than women under the age of 45, after this age, it is more common in women than men <sup>(6)</sup>. Common treatments aimed to reduce pain, improve function, and maintain joint mobility include pharmacological, non-pharmacological methods (training program, regular exercise, physiotherapy, lifestyle modification), PRP, surgery, and cell therapy <sup>(7,8)</sup>.

Tabriz, Iran

\*Corresponding author:  
Dr. Davood Asgari  
Email:  
d.asgarii618@gmail.com

A human study by Jo et al., Mesenchymal cells have been extracted from the adipose tissue for 18 patients with osteoarthritis and injected into their knees at three different doses. . The results showed that injecting high dose mesenchymal cells repaired cartilage in a layer similar to clear cartilage in the inner part of femur and tibia bones. It was also significantly effective in increasing performance and reducing pain in these patients <sup>(9)</sup>. Zhou et al. performed three types of treatment methods to repair cartilage by creating a hole by 0.8 mm deep and 4.5 mm in diameter with a drill in the knee of 27 rabbits. For the first group: microfracture treatment method has been used, and for the second group: microfracture and mesenchymal cells located on the scaffold layer and in the third group only the scaffold therapy technique. . The healing process was followed according to the ICRI rating and finally the group in which a combination of the two treatment techniques was used significantly and rapidly restored than the first and third groups <sup>(10)</sup>. In 2009, Zhang et al. reproduced adipose-derived mesenchymal cells in culture medium, combined them with calcium alginate gel, and injected them into 27 rabbits. The injury have been located at the femoral patellar cartilage of the knee. Macroscopic and microscopic examination of cartilage repair was performed 4, 8 and 12 weeks later. Statistical analysis showed that the repair has been conducted by cell proliferation and formation of collagen fibers and with  $P < 0.01$  the difference was significant between control and experimental groups <sup>(11)</sup>. Sato et al. labeled mesenchymal cells suspended in PBS and hyaluronic acid with fluorescence and injected into the pig knee joint. The studies were performed in three stages after 1, 3 and 5 weeks after injection. Type II collagen is proliferated and increased and also surrounded chondrocytes and mesenchymal cells <sup>(12)</sup>. Hamoud et al. injected mesenchymal stem cells cultured in basal culture medium and chondrogenic culture medium at a dose of 10 million cells in 5  $\mu$ l of

fluid into the osteoarthritis knee joint in 12 sheep. Macroscopic and microscopic studies were performed and compared in two experimental groups. The results showed that the injection of stem cells in chondrogenic culture medium caused more cartilage repair than the group of stem cells in the basic culture medium <sup>(13)</sup>. Van Buul et al. investigated the effect of mesenchymal cells and mononuclear cells extracted from bone marrow on pain relief, reduction of cartilage damage, bone changes and inflammatory changes in rats with osteoarthritis. Three weeks after MIA injection, three groups have been evaluated: 1- MSC-receiving group, 2- monoclonal cell-receiving group and 3- control group. After 4 weeks of receiving, the knee of rats with osteoarthritis was examined. Among these, only mesenchymal cells caused significant weight gain in the limb with osteoarthritis, however, lesion repair, synovial inflammation and subchondral bone repair were not significant <sup>(14)</sup>. In the present study, mesenchymal cells have been considered to understand the effectiveness of stem cells in the treatment of osteoarthritis. Due to the trophic secretions of stem cells, for the first time, the secretions of these cells have been investigated without the presence of stem cells as a possible technique for the treatment of osteoarthritis.

## Methods

In this experimental study, 30 adult male rats from the animal house for Urmia University of Medical Sciences were used weighing approximately 200-200 g. The rats were kept in the same conditions and given equal water and food. The animals were randomly divided into five groups of 6 rats as follows:

- Group A: Healthy control group: Physiological serum injection
- Group B: Osteoarthritis Group (OA): Intra-articular injection of 1 Monosodium Iodo acetate (MIA)

- Group C: Mesenchymal group (MSCs): MIA injection and MSCS injection in the main culture medium two weeks after MIA injection

- Group D: Mesenchymal group + receiving the same volume of cell secretions + culture medium (M + C.S.): MIA injection and MSCS secretion injection + culture medium two weeks after MIA injection

- Group E: Culture medium group (M): MIA injection and culture medium injection two weeks after MIA injection

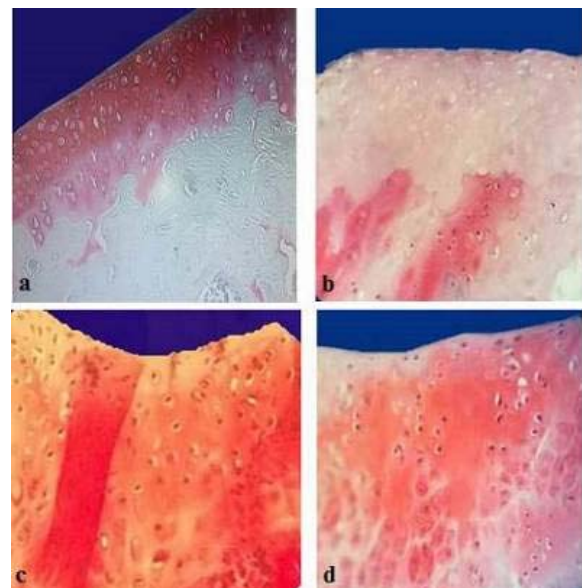
Two weeks after MIA injection, it was injected in group C (MSCs) cultured mesenchymal stem cells  $2.5 \times 10^5$  and in group D (M + CS) stem cell secretions and culture medium, and in group E (M) culture medium into the damaged joint. Group A (healthy control) animals received simultaneous physiological serum injections. 4 weeks later, the animals were anesthetized and then killed, their left knee, which included the distal femur and proximal tibia, was carefully removed with special scissors and their soft tissue removed from the knee to facilitate patellar joint fixation. At this stage, the ends of the femur and tibia bones were examined macroscopically by stereomicroscope and cartilage repair. Sections prepared by different staining methods including hematoxylin-eosin, trichrome malori and toluidine blue and safranin and the classifications according to (ICRS) are as follows: Cartilage health: 4, cartilage surface fibrillation: 3, small and superficial cracks: 2, large and deep or multiple small cracks: 1, complete cartilage destruction: 0. Finally, they have been observed and examined by light microscope.

It should be noted that in the present study, the data distribution was investigated using the Kolmogorov-Smirnov (k-s) method. Data on the variables of width and depth, number of chondrocytes, had a normal distribution and parametric tests, ANOVA, T-Test, Tukey (SPSS software version 16) were used for their analysis.

## Results

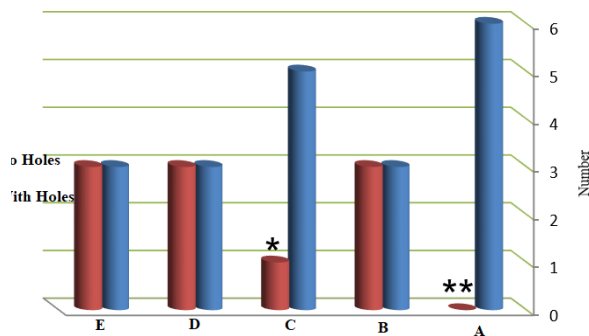
The effect of injection of mesenchymal cells extracted from bone marrow and secretions from these cells without mesenchymal cells on rat knee osteoarthritis has been investigated in the present study. Topical injection of MIA, a glycolysis inhibitor, disrupts chondrocyte metabolism and demolishes the cartilage. In this study, after injecting one milligram of MIA into the space inside the knee joint, cartilage lesion repair in the femur bone was examined after two weeks with two therapies: 1- cell therapy by bone marrow mesenchymal cells, 2- through secretions from mesenchymal stem cells.

Decreased amount of proteoglycans in different layers of cartilage that was observed after osteoarthritis in microscopic samples with safranin-O staining. Light microscopy images of rat femoral articular cartilage in groups A and experiments 14 days after MIA injection are given in Figure (1).



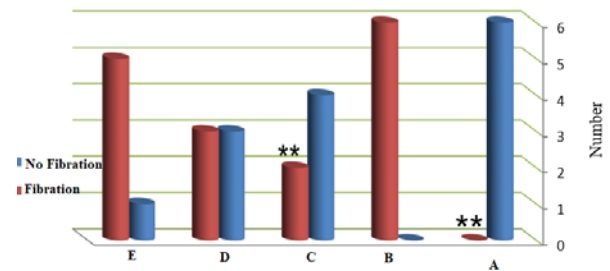
**Figure 1: Comparison of light microscope images of rat femoral articular cartilage in control and experimental groups 14 days after MIA injection. a) Group A, b) Group B, c) Group C, d) Group D (Safranin-O staining, \*100 magnification)**

In Figure 1, in the healthy group (physiological serum injection) (group A), the proteoglycans in the various layers of cartilage are completely red (purple), and in OA group (MIA injection) (group B) decrease in proteoglycan staining and lack of chondrocytes is evident in different layers. In the MSCs group (injection of MIA and MSCs) (group C) there was an increase in proteoglycans and the number of chondrocytes in the cartilage layers and in the group M + C.S. (Injection of MIA and M + C.S.) (Group D) a relative increase in proteoglycan and chondrocyte count is observed in the deep layers and the surface layer is still colorless. In the repair group with injection of MSCs due to blood supply and release of bone marrow mesenchymal cells in the subchondral region, the healing process was significant ( $P < 0.05$ ) compared to other groups (Figure 2).

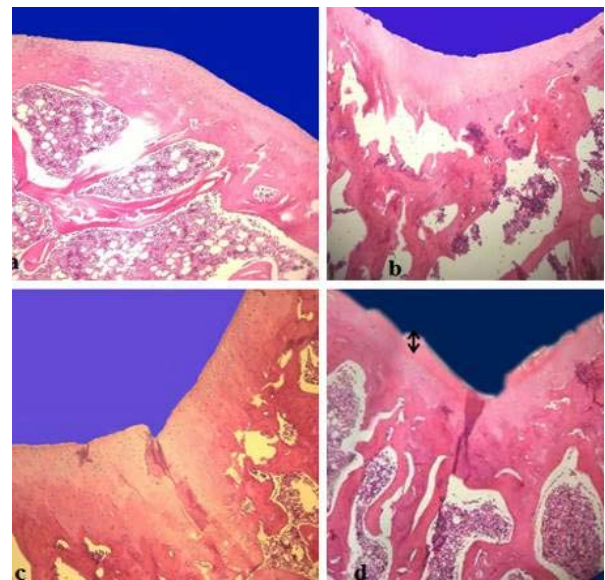


**Figure 2: Comparison of the presence of deep cavities in control and experimental groups**

In the repair group with MSCs injection, a significant reduction has been observed in fibrillation ( $P < 0.05$ ). In the repair group by injection of cell secretions and culture medium, the repair was relative, but in the repair group, no serious changes have been observed by injection of culture medium (Figure 3).



**Figure 3: Comparison of fibrillation in control and experimental groups**

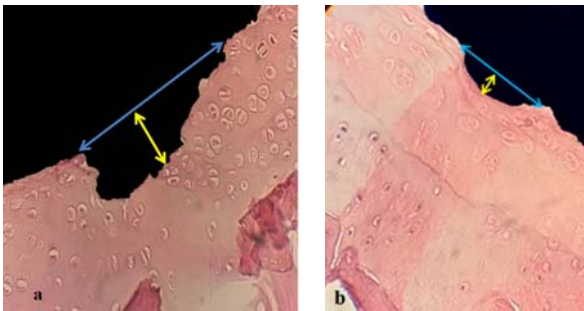


**Figure 4: Comparison of light microscopy images of rat femoral articular cartilage in control and experimental groups 14 days after MIA injection. a) Group A b) Group B, c) Group C, d) Group D (H&E Staining, \*40 magnification)**

In Figure (4), it could be observed that in the group A (physiological serum injection) the articular cartilage is thick and chondrocytes are visible in large numbers in different layers; and in group B, there is a decrease in cartilage thickness, a severe decrease in chondrocytes and a decrease in cartilage surface staining. In addition, in the group C, increased cartilage thickness, cartilage tissue staining and an increase in the number of chondrocytes. Also in the group D, a two-way arrow indicates cartilage surface regeneration in which a small



number of chondrocytes are visible in this layer.



**Figure 5: Comparison of the depth and width of the femoral articular cartilage destruction site 14 days after MIA injection and repair of the damaged area 4 weeks after MSCs injection into the rat femoral joint, a) blue arrow of the destruction area width and yellow arrow of the cavity depth Shows the destroyed. b) The blue arrow shows the width of the repaired area and the yellow arrow shows the reduction in lesion depth 4 weeks after MSCs injection (E & H Staining, \*400 magnification)**

## Discussion

The histopathological changes caused by MIA injection are entirely time dependent. MIA is an inhibitor of 3-phosphate dehydrogenase glyceraldehyde and by inhibiting glycolysis leads to the death of chondrocytes, bone trabeculae with fibrosis and an increase in osteoclasts, the formation of new trabeculae and subchondral cysts<sup>(15)</sup>. In a study by Peggy et al., by applying weight to the cartilage surface, a decrease in proteoglycan has been observed first at the cartilage surface and by increasing the load, the decrease was also observed in the deep layers<sup>(16)</sup>. Osteoarthritis initially causes changes in the extracellular matrix, and as chondrocytes are located within the matrix, these changes in turn affect the chondrocytes and advance the disease. Aggrecan can absorb water and play anti-shock role against weight, and in osteoarthritis, the amount of this factor decreases and therefore

cartilage loses weight-bearing capacity (Figure 1).

According to Figure (2), deep cleft type demolition occurs in the final stages of osteoarthritis and is associated with severe pain due to nerve involvement. Deep degradation has been observed in a number of specimens affected by MIA injection. The superficial layers have been destroyed and the subchondral region was visible. This type of degradation has been observed in approximately three heads of group B rats. By  $k^2$  test, there was a significant difference between groups A and C and group B, which was not significant in groups D and E. In the present study, a significant increase for proteoglycans has been observed by mesenchymal cell injection, the reason was the ability of MSCs to convert to chondrocytes, and osteoblasts and the newly replaced cells gradually begin to secrete an extracellular matrix<sup>(17)</sup>.

In Figure (3) according to the ICRS classification, fibrillation is one of the primary changes in osteoarthritis that was observed in most of the slides prepared with different colors after the time of degradation (14 days). This pathological condition is accompanied by the accumulation of chondrocytes in clusters in some parts of the cartilage, while the adjacent parts lack chondrocytes. Fibrillation was one of the primary changes in OA (significant increase in cellular fibrillation) and it was observed in all samples of group B that with  $k^2$  test there is a significant difference between groups A and C with group B. In the repair group with cell secretions and culture medium, the reduction of fibrillation was relative and not significant, and no serious changes have been observed in the repair group with culture medium. By adding the protein kinase, Anfield et al. reduced the adhesion of chondrocytes to fibronectin, thereby creating a disorder in the chondrocytes. Chondrocytes in this cluster state cannot go to the affected area<sup>(18)</sup>. The occurrence of such a condition was quite

evident in our study and was significantly reduced by injection of mesenchymal stem cells, which is probably due to a decrease in the amount of inflammatory molecules and enzymes.

In the present study, MSCs were injected directly into the knee joint with osteoarthritis, and satisfactory results were obtained in repairing damaged cartilage areas, which were somewhat consistent with previous studies in this field. In his research, Zhang injected  $2 \times 10^6$  MSCs cells into the knee of 27 rabbits after 12 weeks and found that macroscopically and microscopically the articular cartilage pores and cavities were completely filled with tissue similar to normal cartilage tissue<sup>(11)</sup>.

As mentioned before, the secretions from mesenchymal cells were able to fill the cartilage pores to some extent and there were no signs of inflammatory cells in this study. It seems that mesenchymal stem cells in the joint space with the ability to find the location of the lesion were able to enter the pores and cavities caused by osteoarthritis and in those areas to find the approximate morphology of chondrocytes<sup>(19)</sup>. In addition, in the macroscopic observations in the cell therapy group, the deep cavities were filled with a jelly-like matrix and the surface of the cartilage was relatively white and smoother in appearance.

In the report of Abir et al., an increase in chondrocytes and an increase in the color of the matrix after two months have been reported in the stem cell recipient group<sup>(20)</sup>. Topical injection of stem cells in people with osteoarthritis repairs and prevents the disease from progressing. Van Buul also studied the effect of mesenchymal cells and mononuclease extracted from rat bone marrow on reducing pain and inflammation caused by osteoarthritis and found that injection of these cells significantly reduced pain and increased lower limb diameter with osteoarthritis<sup>(14)</sup> that all are in line with the results of the present study. It should be noted that in previous research, human clinical

studies to investigate the effect of mesenchymal cells have rarely been performed, and the need to address this issue in the treatment of osteoarthritis is of particular importance.

## Conclusion

Histological studies showed that the rate of fibrillation, the presence of small gaps and deep gaps ( $P < 0.05$ ) decreased in the mesenchymal treatment group. In addition, the amount of proteoglycans in mesenchymal group therapy increased significantly ( $P < 0.05$ ). Morphometric studies also showed that the number of chondrocytes in the mesenchymal group increased significantly ( $P < 0.05$ ). Decreasing the depth of deep cavities of the inner condyle of the femur ( $P < 0.10$ ) was significantly different from the osteoarthritis group, while the width of the destruction area was not significantly different from the osteoarthritis group.

## References:

- [1] Keith Sinusas MD .Middlesex Hospital, Middletown, Connecticut. Osteoarthritis: Diagnosis and Treatment. American Family Physician . 2012 ; 85 (1): 49-56.
- [2] Johannes WJ, Berenbaum F, Floris PJG. Osteoarthritis: an update with relevance for clinical practice. 2011; 377 : 2115-26
- [3] Thomas J, Zuber MD, Saginaw Cooperative Hospital, Saginaw, Michigan. Knee Joint Aspiration and Injection. 2002; 66 (8) :1497- 99.
- [4] Koopman WJ, Arthritis & allied Conditions/ Lippincott william's and wilkins: Philadelphia;London. 2001; 2246 -2263.
- [5] Salter1 DM, Heng-Sheng L. Pathology and Risk Factors in Osteoarthritis . J Med Sci. 2012; 32(5): 199-207.
- [6] Pang J, Yi C, Shi YY, HoujwW, Shi Y. Contorl study for muscle force and Component of body femals Patients with knee osteoarthritis . hongguoGu shang. 2008; 21 (11) : 828 – 30.
- [7] Tehrani-Banihashemi A, Davatchi F, Jamshidi AR, Faezi T, Paragomi P, Barghamdi M. Prevalence of osteoarthritis in rural areas of Iran: a WHO-ILAR Copcord study. 2014; 17(4):384-8.

[8] Hardingham A, Tews MA. Regional variations of collagen orientation in normal and diseased articular cartilage and subchondral bone determined using small angle x-ray scattering (SAXS) in osteoarthritic cartilage. *Journal of Orthopaedic Research*. 2007; 12(6): 682 – 687 .

[9] Jo CH, Lee YG, Shin WH, Kim H, Chai JYY, Jeong EC. Intra-articular injection of mesenchymal stem cells for the treatment of osteoarthritis of the knee : a proof - of - concept clinical trial . *Stem Cells*. 2014; 32(5):1254- 66.

[10] Shi J, Zhang X, Zeng X, Zhu J, Yanbin PI, Zhou C. One – step Articular Cartilage Repair : Combination of In Situ Bone Marrow Stem Cells With Cell-free Poly (L-Lactic-co-glycolic Acid) Scaffold in a Rabbit model .*Orthopedics*. 2012; 35 (5) :665-671.

[11] Zhang H, Li L, Leng P, Wang Y, Lucheng Y. Uninduced adipose derived stem cells repair defect of full thickness hyaline cartilage .*Chinese Journal of Traumatology*. 2009; 12(2):92-97.

[12] Sato M, Uchida K, Nakajima H, Miyazaki T, Rodriguez Guerrero A, Watanabe S. Direct transplantation of mesenchymal stem cells into the knee joints of Hartley strain guinea pigs with spontaneous osteoarthritis. *Arthritis Res Ther*. 2012; 14(1): R31.

[13] Hamoud AL, BinMohamad Y, Hui Cheng C, Bin Saim A. Bt Hj Idrus, R. *Experimental Gerontology*. 2012; 47: 458-467.

[14] Van Buul, GM, Siebelt, M, Leils, MJ, Bos, PK, Waarsing, JH, Kops, N. Mesenchymal stem cells reduce pain but not degenerative changes in a mono-iodoacetate rat model of osteoarthritis. *J Orthop Res*. 2014; 32(9):1167-74.

[15] Guzman E, Evans R, Brandy Morenko MG, Kilgor SK. Mono-Iodoacetate-Induced Histologic Changes in Subchondral Bone and Articular Cartilage of Rat Femorotibial Joints: An Animal Model of Osteoarthritis. *Toxicologic Pathology*. 2003; 31:619-624.

[16] Peggy M, Lin Chen C, Torzilli PA. Increased stromelysin-1(MMP-3), proteoglycan degradation (3B3-and 7D4) and collagen damage in cyclically load-injured articular cartilage. *Osteoarthritis and Cartilage*. 2004; 12:485-496.

[17] Maldonado M, Nam J. The Role of Changes in Extracellular Matrix of Cartilage in the Presence of Inflammation on the Pathology of Osteoarthritis. *Journal of Cellular Biochemistry*. 2013;8:249-259.

[18] Anfield M, Richard M, Vignon E . Osteoarthritic cartilage fibrillation is associated with a decrease in chondrocyte adhesion to

fibronectin. *Osteoarthritis and Cartilage*.1998;6:393-399.

[19] Constance R, Chu MD, Michal Szczodry MD, Stephen Bruno BA. Animal Models for Cartilage Regeneration and Repair. *Tissue Eng Part B Rev*. 2010;16(1):10- 21.

[20] Abir NM, Omar S, Tookhy EI, Ashraf A, Shama L, Rashed A, Sabry D, El Sayed AM. Homing and reparative effect of intra-articular injection of autologous mesenchymal stem cells in osteoarthritic animal model .*BMC Musculoskelet Disord*. 2011; 12: 259- 67.