

Effect of topical zoledronic acid on spinal fusion of osteoporotic patients: A Randomized clinical trial

Abstract

Background: Spinal fusion is a surgical method to treat degenerative diseases of the spine. We studied the effect of bone graft soaked with zoledronic acid (ZA) on spinal fusion.

Method: 60 patients with degenerative disease, scheduled for spinal fusion were randomly divided into 2 equal groups, receiving either local bone graft or local bone graft plus topical zoledronic acid. The cases were studied with visual analogue scale (VAS), Oswestry low back disability questionnaire, and radiographic bone bridge formation with a 12-months follow-up.

Results: 57 patients completed the study: 27 patients in "control group" and 30 patients in "case group". VAS Score was significantly lower in case group in comparison with control one after 12 months (P value:0.00). In the point of Oswestry low back disability questionnaire score (ODI) score the mean score was decreased significantly in "case group" in comparison with "control group" (P value =0.006). Radiographic grades A or B bone bridging was more frequently observed in Zoledronic acid group at 12 months post-operation compared with the control group (p value=0.00).

Conclusion: This study demonstrates that addition of Zoledronic Acid to bone grafting in the spinal fusion of elderly people increases the fusion rate and is associated with better clinical and functional outcome.

Keywords: Osteoporosis, zoledronic acid, spine, lumbar, fusion

Received: 10 months before printing; Accepted: 20 days before printing

*Adel Ebrahimpour, MDI; *Ahmadreza Mirblock, MD; *Alirza Manafi, MD;
**Bahamin Attar, MD; *Gholamhossein Kazemian, MD

Introduction

*Associate professor of orthopaedic surgery, Shahid Beheshti university of medical sciences, Tehran, Iran.

**Spine fellowship, orthopaedic surgery, Shahid Beheshti university of medical sciences, Tehran, Iran.

* **Correspondence**
Gholamhossein Kazemian, MD
gh_kazemian@yahoo.com

Spinal lumbar fusion is a surgical method to eliminate the lumbar instability or deformity⁽¹⁾. The common reasons for this surgery include degenerative disk disease, spondylolisthesis, spinal stenosis, scoliosis, fractured vertebrae, tumor and herniated disk. Osteoporosis is accompanied with many diseases and may cause failure of spinal fusion surgery^(1, 2).

Autologous iliac crest bone is the gold standard for spinal bone fusion. Complications in the donor site such as infection, hematoma, and fracture have led to decreased tendency towards autologous bone graft usage, especially in osteoporotic patients^(1, 2). The other usual methods to decrease failure rate in such osteoporotic patients are the use of as bone cement augmentation, and bone morphogenetic proteins (BMP)^(1, 3, 4).

Osteoporosis is a systemic metabolic disease treated with anti osteoporotic agents such as bisphosphonates. The main mechanism of these drugs is inhibiting osteoclastic activity. Zoledronic acid is a third generation bisphosphonate, used in different animal and human studies and has been shown to increase fusion mass and mineral content of the bone⁽⁵⁾. Although some studies have shown good results with intravenous infusion of zoledronic acid for bone fusion of patients with osteoporosis, it may have systemic complications and its effect on the fused bone is unclear. The main purpose of this study is to evaluate topical administration of zoledronic acid in osteoporotic patients who undergo spinal fusion surgery.

Method

In a randomized clinical trial, the patients with osteoporosis and spondylolisthesis unresponsive to conservative treatment and scheduled for spinal fusion from November 2017 to December 2019 in Imam-Hossein Hospital in Tehran were included in the study. Informed written consent approved by the University ethics committee were obtained for all the cases. The inclusion criteria was: Lumbar degenerative disease with osteoporosis in one or two levels. The exclusion criteria were: Non degenerative disease such as cancer, infection, trauma, osteoporosis secondary to metabolic disease, history of Zolendronic Acid use.

60 osteoporotic patients with degenerative disease were randomly divided into 2 groups: local allograft soaked with Zoledronic Acid (ZA) and local bone graft alone (controls). 57 patients completed the study: 27 patients in “control group” and 30 in “case group”(Table1).

Table1. Demographic data of patients		
	Case group	Control group
Age(years)	60±6	63±3
Gender	11(male) 16(female)	10(male) 17(female)
Level of surgery		
L4-I5	16	11
L5-s1	14	16

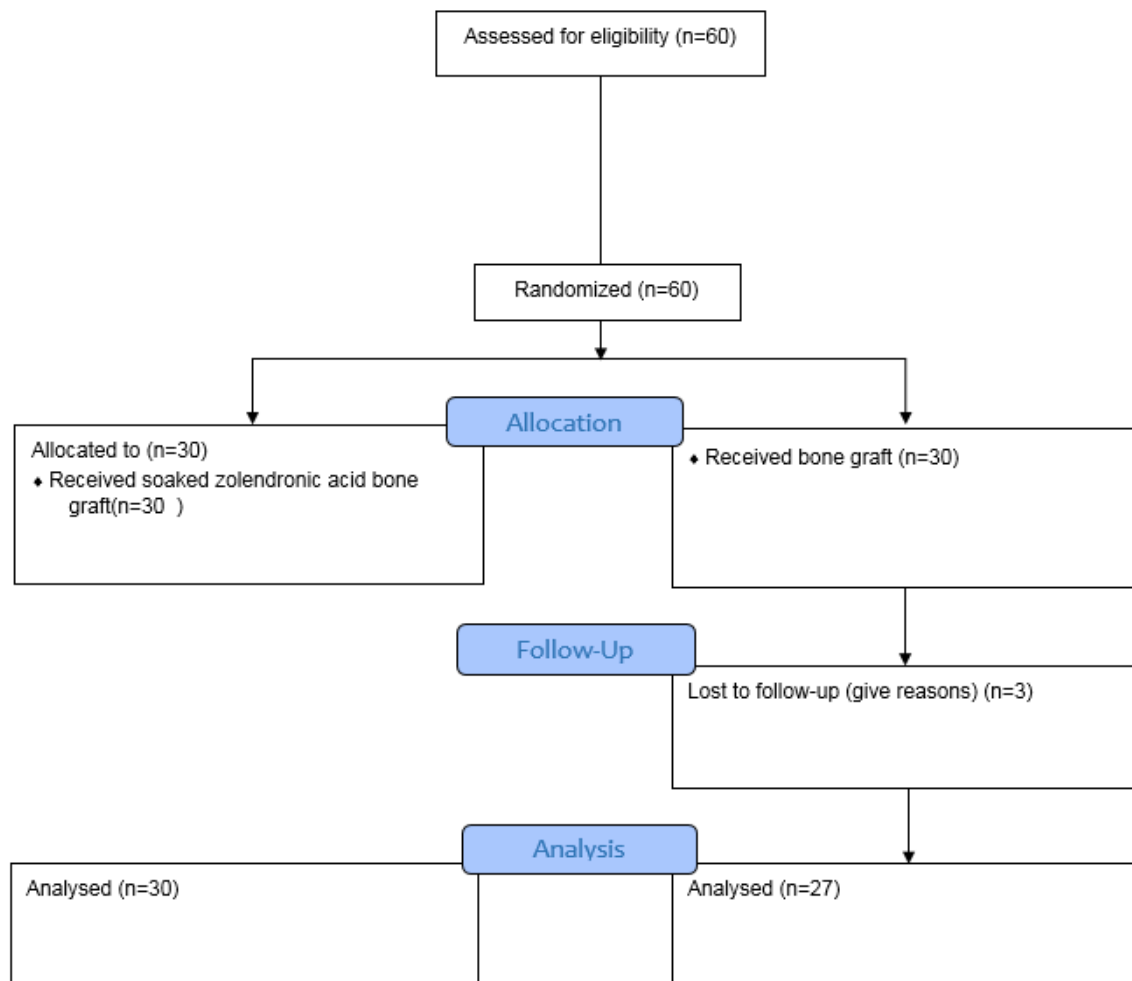


Fig 1. Consort diagram of participants

3 patients in control group were lost to follow up (fig1).

Through posterior approach, allograft bone, soaked in ZA solution for 5 minutes, were put inside Titanium posterior lumbar interbody fusion cage (Canwell company) and then the cage was packed into the disk space for interbody fusion and then posterior instrumentation was done. In posterolateral fusion after laminectomy, instrumentation and decortication of transverse process, bone graft which has been soaked in ZA were put into the decorticated field. Radiographic post-operative images were taken at the beginning and then 12 months after surgery. CT scan (computed tomography) was also obtained at 12 months.

VAS score and ODI score were used for clinical assessment before surgery, 6 months and 12 months after surgery. Bone form at ionon radiographs, categorized according to Lenke assessment was graded into 4 categories: Grade A definitely solid (solid big trabeculated bilateral fusion masses), Grade B Possibly solid (unilateral large fusion mass with contralateral small fusion), or Grade C

(probably not solid: small thin fusion masses bilaterally), Grade D (definitely not solid: graft resorption bilaterally or fusion mass obviously bilateral pseudarthrosis CT Scan included: Grade A (bridging bone bonding with adjacent vertebral bodies), Grade B (bridging bone bonding with either superior or inferior vertebral body), or Grade C (incomplete bony bridging).

The results are presented as mean \pm standard deviation (SD). Non-parametric tests were used to compare the difference between case and control groups. Significance of difference in frequency between groups was evaluated with 2-tail Fisher's exact test. The SPSS 16.0 software package (SPSS Inc., Chicago, IL, USA) was used for statistical analyses.

Results

Table 1 showed demographic characteristics of all participants. Mean age of case group was 60, control one was 63 years old. VAS Score was significantly lower (20.57) in case group in comparison with control one (38.37) after 12 months (p value:0) (fig2).

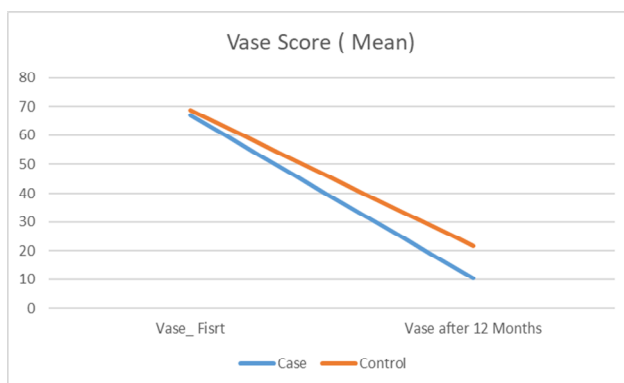


Fig2. VAS Score at 12 months postoperatively was significantly better in the zoledronic group than in the control group (p=0.00)

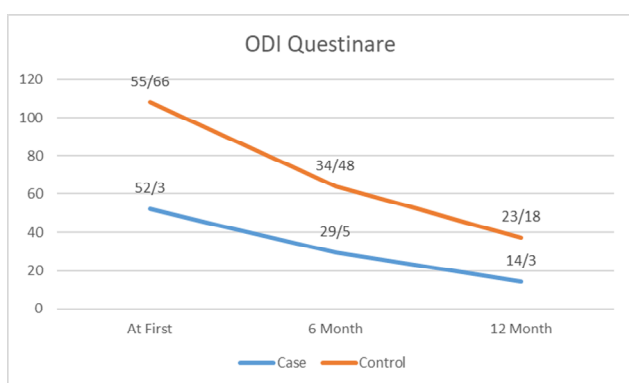


Fig 3. ODI score were different between the two groups and has been decreased in each group.

In the point of ODI questionnaire, the mean ODI score was lower significantly in case group (21.83) in comparison with control one(36.96)(p value:0.006)(fig3).

Grade A or B bridging bone in radiography assessment was more frequently observed in ZA group, compared to the control group at 12 months (p :0.00)(fig4,5)(fig6,7).

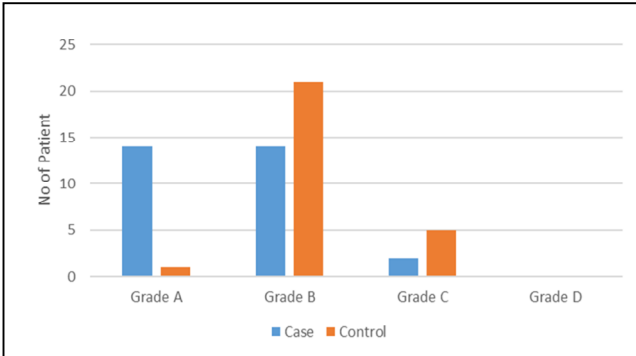


Fig 4. Radiographic assessment of bone fusion after 12 months

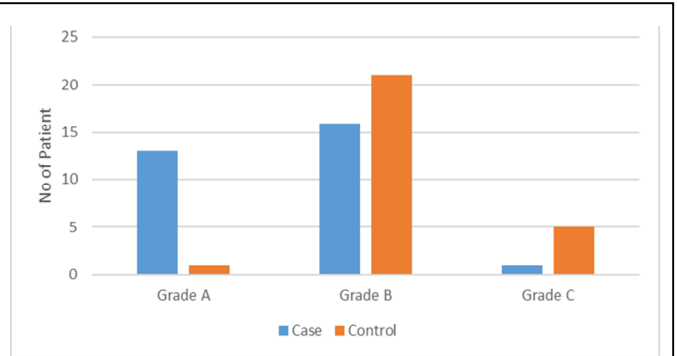


Fig 5. Grade A or B bone formation in CT SCAN is significantly more observed in the zoledronic acid group at 12 months in comparison with control one.

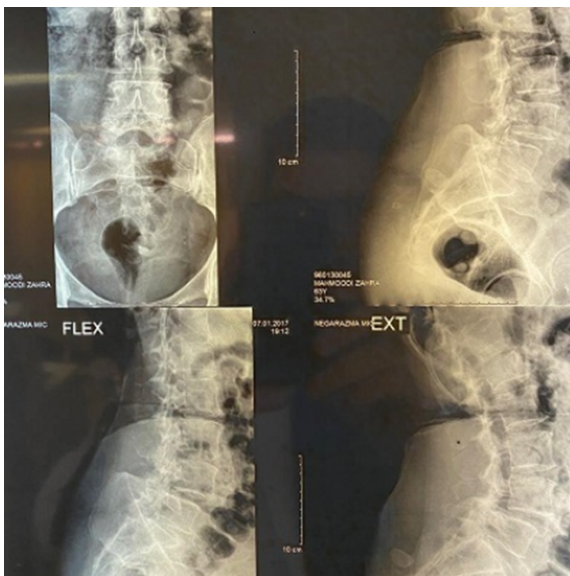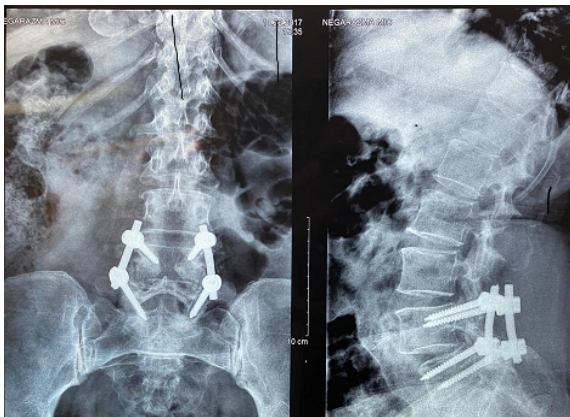


Fig 6 a, b. L4-L5 spondylolisthesis before surgery and 12 months after surgery in case group.

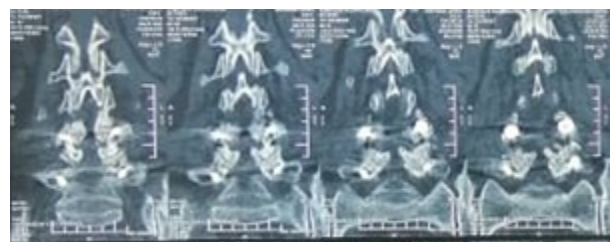
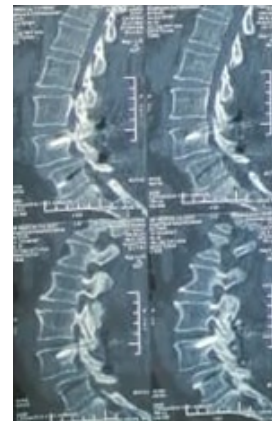

Fig7. Grade B fusion in case group as evaluated using computed tomography.

Discussion

In the present study, soaked bone graft of zoledronic acid promoted bone fusion in osteoporotic fusion during 1 year follow-up period. There was a significant decrease in low back pain and ODI between groups. Moreover, better fusion was seen in radiographic assessment.

Autograft expanders such as allografts, ceramics, demineralized bone matrix, recombinant human bone morphogenetic proteins and cultured stem cells are nowadays used more frequently instead of traditional autologous iliac crest bone graft. These methods can be complicated by donor site pain and significantly increased costs, respectively. Therefore, bisphosphonates have been used and shown to increase allograft fusion rate^(6, 7). The main purpose of degenerative spinal disease surgery is achieving solid union. Our study is the first randomized controlled trial to evaluate the effect of topical ZA on spinal fusion in human. Imbalance between bone resorption and formation is necessary for bone fusion. Bisphosphonates can be used after surgery to prevent bone resorption. Previous invitro studies with alendronate showed good effect on size and density of the fusion mass on pigs⁽⁸⁾.

A human trial investigated alendronate effect on bone fusion, and showed better fusion rate and clinical outcome⁽⁹⁾. It acts by inhibiting bone resorption and osteoclast activation. Zoledronic acid as a third generation bisphosphonate acts differently in comparison with other bisphosphonates. It increases mineralization, remodelling and bone mineral content⁽¹⁰⁾. Significant improvement in spinal fusion and decrease pedicle screw loosening

was reported after Zoledronic infusion with no difference in implant fixation failure rate between groups⁽¹¹⁾.

In previous studies, the effect of ZA on spinal fusion rate in animals has been investigated^(12, 13). In a study by Park et al, patients were divided into 4 groups. One group received lumbar fusion bone graft and a single dose of systemic administration of zoledronic acid 2 weeks after surgery. They reported no difference in VAS, ODI and SF-36 (short-form questionnaire) score after surgery⁽¹⁴⁾.

In other study that was published in 2016 by Chen et al. radiography and CT scan were used to evaluate bone fusion and also serum level of carboxy terminal telopeptide of collagen was measured. Duration of time to infusion was shorter and also clinical outcome in osteoporotic patients was better⁽⁵⁾.

In other study in 2017 by Ding et al, 30 patients received intravenous Zoledronic Acid at the 3rd-5th day after lumbar spinal fusion surgery. VAS, ODI and SF-36 scores were recorded. That study showed significant improvement at 12 months, but not at 6 months in case group in comparison with control (which was with saline) group⁽²⁾.

In rabbit models, the effect of topical ZA (20 µg) with hyperbaric oxygen was assessed, which showed better spinal fusion⁽¹²⁾.

In a study by Zwolak, posterolateral fusion was done in murine model. 3 groups were designed. Group 1 received decortication, group 2, decortication and collagen carrier, group 3 decortication, collagen carrier with soaked bone graft of ZA in 10 µg. They reported new bone formation after a single application of topical Zoledronic Acid⁽¹⁵⁾. Our study showed that topical zoledronic acid has a positive effect on increasing bone density after 12 months with the highest anti-resorptive

activity. It has shown minimal adverse effects. It is clear that mild symptoms of pyrexia, myalgia, arthralgia and influenza-like syndrome were the most common adverse effects of systemic zoledronic acid administration. Serious side effects such as atrial fibrillation, sudden cardiac arrest and stroke have been reported with parenteral use⁽¹⁶⁾. Using topical form would eradicate such complications.

Limitation:

This study has its limitations. The sample is small and also the follow-up time over 12 months is relatively short.

Conclusion

In conclusion, application of bone graft which have been soaked in Zoledronic Acid improve- both radiographically and clinically- the outcome of spinal fusion surgery.

References

1. Ponnusamy KE, Iyer S, Gupta G, Khanna AJ. Instrumentation of the osteoporotic spine: Biomechanical and clinical considerations. *Spine J*. 2011;11(1):54-63.
2. Ding Q, Chen J, Fan J, Li Q, Yin G, Yu L. Effect of zoledronic acid on lumbar spinal fusion in osteoporotic patients. *Eur Spine J*. 2017;26(11):2969-77.
3. Carlisle E, Fischgrund JS. Bone morphogenetic proteins for spinal fusion. *Spine J*. 2005;5(6 Suppl):240S-9S.
4. Deyo RA, Ching A, Matsen L, Martin BI, Kreuter W, Jarvik JG, et al. Use of bone morphogenetic proteins in spinal fusion surgery for older adults with lumbar stenosis: Trends, complications, repeat surgery, and charges. *Spine*. 2012;37(3):222-30.
5. Chen F, Dai Z, Kang Y, Lv G, Keller ET, Jiang Y. Effects of zoledronic acid on bone fusion in osteoporotic patients after lumbar fusion. *Osteoporos Int*. 2016;27:1469-76.
6. Ito Z, Imagama S, Kanemura T, Hachiya Y, Miura Y, Kamiya M, et al. Bone union rate with autologous iliac bone versus local bone graft in posterior lumbar interbody fusion (PLIF): A multicenter study. *Eur Spine J*. 2013;22:1158-63.
7. An HS, Lynch K, Toth J. Prospective comparison of autograft vs. allograft for adult posterolateral lumbar spine fusion: Differences among freeze-dried, frozen, and mixed grafts. *J Spinal Disord*. 1995;8:131-5.
8. Xue Q, Li H, Zou X, Dalstra M, Lind M, Christensen FB, et al. Alendronate treatment improves bone-pedicle screw interface fixation in posterior lateral spine fusion: An experimental study in a porcine model. *Int Orthop*. 2010;34:447-51.
9. Nagahama K, Kanayama M, Togawa D, Hashimoto T, Minami A. Does alendronate disturb the healing process of posterior lumbar interbody fusion? A prospective randomized trial. *J Neurosurg Spine*. 2011;14:500-7.
10. Recker RR, Delmas PD, Halse J, Reid IR, Boonen S, García-Hernandez PA, et al. Effects of intravenous zoledronic acid once yearly on bone remodeling and bone structure. *J Bone Miner Res*. 2008;23:6-16.
11. Liu WB, Zhao WT, Shen P, Zhang FJ. The effects of bisphosphonates on osteoporotic patients after lumbar fusion: A meta-analysis. *Drug Des Devel Ther*. 2018;12:2233-40.
12. Yalçın N, Öztürk A, Ozkan Y, Çelimli N, Ozocak E, Erdoğan A, et al. The effects of zoledronic acid and hyperbaric oxygen on posterior lumbar fusion in a rabbit model. *J Bone Joint Surg Br*. 2011;93:793-800.
13. Bransford R, Goergens E, Briody J, Amanat N, Cree A, Little D. Effect of zoledronic acid in an L6-L7 rabbit spine fusion model. *Eur Spine J*. 2007;16:557-62.
14. Park YS, Kim HS, Baek SW, Kong DY, Ryu JA. The effect of zoledronic acid on the volume of the fusion-mass in lumbar spinal fusion. *Clin Orthop Surg*. 2013;5:292-7.
15. Zwolak P, Farei-Campagna J, Jentsch T, von Rechenberg B, Werner CM. Local effect of zoledronic acid on new bone formation in posterolateral spinal fusion with demineralized bone matrix in a murine model. *Arch Orthop Trauma Surg*. 2018;138:13-8.
16. Tanvetyanon T, Stiff PJ. Management of the adverse effects associated with intravenous bisphosphonates. *Ann Oncol*. 2006;17:897-907.