

Traumatic Obturator Hip Dislocation with Femoral Nerve Palsy A Rare Case Report

Abstract

Obturator type traumatic anterior hip dislocation in adult is rare of all type hip dislocation. Here we report the case of a 30 year old man brought to the emergency department after motor accident, complaining of left hip pain. The X RAY showed an obturator hip dislocation. Femoral pulse was weaker than the other side and had paresthesia in anteromedial of thigh and could not extend left knee. Dislocation was reduced under general anesthesia. Traction was applied for two weeks. After 1 month he could extend left knee and sensation was regained in anteromedial of thigh.

Key word: hip dislocation, Femoral nerve, paresthesia

Received: 4 months before printing; Accepted: 20 days before printing

Omidreza Momenzadeh, MD*; Mohamad Hadi Gerami, MD**; Alireza Ghasemiyeh, MD***;
*Bita Hojat Panah, MD***

* Orthopaedic surgeon : Bone and Joint Diseases Research Center, Department of Orthopedic, Shiraz, Iran
**Bone and Joint Diseases Research Center, Department of Orthopedic, Shiraz, Iran.
***Intern: Bone and Joint Diseases Research Center, Department of Orthopedic Shiraz, Iran
*** Anaesthesiologist: Bone and Joint Diseases Research Center, Department of Orthopedic, Shiraz, Iran

Corresponding Author:
Mohamad Hadi Gerami, MD

Email:
dr.hadi.gerami@gmail.com

Introduction

The vast majority of hip dislocations occur from high energy motor vehicle trauma. The position of the hip and the force vector applied, affect the direction of the dislocation. About 10% of hip dislocations are anterior⁽¹⁾. Anterior dislocations are described by their anatomic location, being superior including pubic or sub-spinous or inferior including obturator, thyroid and perineal locations⁽²⁾. Inferior dislocation represents only 2-5% of all hip dislocations⁽²⁾ and obturator dislocation is a very rare condition. The clinical presentation of the injured limb can give important information regarding the likely type and direction of hip dislocation. Anterior hip dislocations are presented as shortened and externally rotated limb⁽¹⁾. According to the previous studies, incidence of nerve injury in traumatic hip dislocation is up to 10% and sciatic nerve is the most common injured nerve. In medical literature there are few documented case of acute femoral nerve palsy secondary to hip dislocation.

Case Report

A 30-year-old man was brought to the emergency ward, Chamran Hospital, Shiraz, Iran, at October 2018 presenting pain in his left hip after motor vehicle accident. Upon arriving, the patient was stable with Glasgow coma scale of 15/15.

Physical examination showed his left hip abducted 20° flexion 0° and external rotation of 10° (Fig. 1). Motion of hip was painful and restricted.

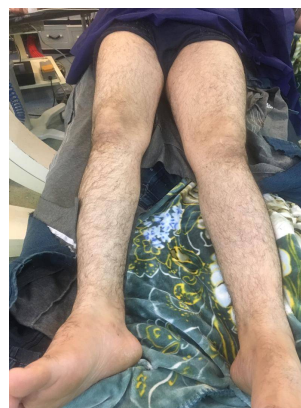

Figure 1: Abduction of left hip in emergency ward before reduction

The femoral pulse was weaker than the other side and neurologic exam showed femoral nerve palsy. Patient had parasthesia in anteromedial of thigh and could not extend left knee without any contraction in quadriceps muscle at arrival. X-ray findings revealed obturator hip dislocation, no associated fracture was seen (Fig. 2).

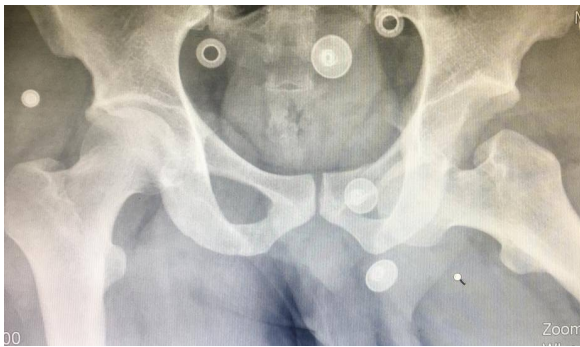

Figure 2: Anteroposterior radiograph of the pelvis showing an obturator dislocation of the left hip

The patient was scheduled for closed reduction under general anesthesia. The patient was informed consciously. The dislocation was reduced by traction in the line of the deformity followed by some flexion. Post reduction x-ray showed concentrically located head of femur in the acetabulum (Fig. 3)

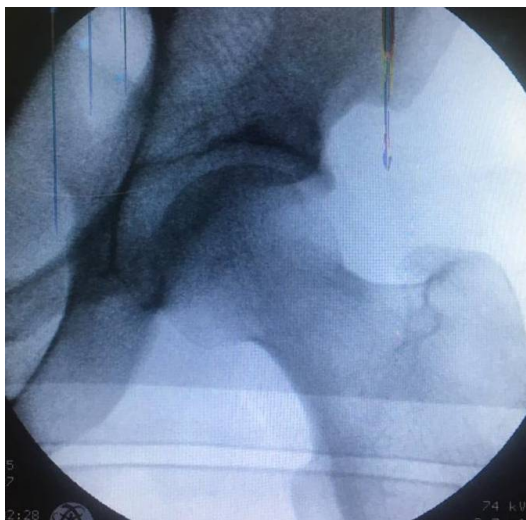


Figure 3: Post reduction radiograph showing the left hip congruency

Femoral pulse became normal but the femoral nerve still showed no sensory and motor function after reduction.

Skin traction was applied for 2 weeks, then progressive mobilization with help of knee brace, walker and partial weight bearing was advised for 3 weeks.

After a 1 month follow up he could extend the knee against gravity and sensation was regained in the medial of his leg and after 4 months the patient came without any complaints of pain, normal range of motion, good power in Quadriceps muscles and complete clinical recovery of femoral nerve.

Discussion

Hip dislocation is an orthopaedic emergency case. Hip dislocation with nerve injury occurs in less than 10% of cases and very few cases of femoral nerve injury have been reported with hip dislocation.

An inferior dislocation is a rare form of hip dislocation, accounting of <5% of all hip dislocations⁽³⁾. Up to December 2018 there were a few published articles concerning femoral nerve palsy secondary to hip dislocation. Dr. Rahimi et al. reported femoral nerve palsy following delayed reduction of the dislocated hip in 2014⁽⁴⁾.

Frew et al. reported femoral nerve palsy with posterior hip dislocation⁽⁵⁾.

Stein et al. reported hip dislocation of a ballet dancer with low energy trauma and femoral nerve neuropraxia that resolved within six weeks in 2002⁽⁶⁾.

In previous studies, there has been no case of anterior hip dislocation with femoral nerve injury and femoral pulse weakness at the same time. In this case, after reduction, pulse returns to normal and after 4 months quadriceps muscle strength, knee extension and sense of femoral nerve is normalized.

Inferior hip dislocation can be managed usually with close reduction under general anesthesia. Reduction usually achieved by traction and gradual knee extension with internal rotation.

For patients whose hips have been reduced within 6 hours, the standard post reduction regimen includes a brief period of rest for 2 to several weeks⁽²⁾.

Extremes of motion are avoided for 6 to 8 weeks to allow capsular healing⁽²⁾.

Avascular necrosis is a late complication of hip dislocation and is reported in 1.7 to 40% of various series⁽⁷⁾. If the hip is reduced within 6 hours of dislocation the AVN rates are decreased to 0-10%. Early diagnosis and treatment are important in the management of this injury to prevent avascular necrosis and damage to the femoral nerve⁽⁸⁾.

References

1. Azar, FM., Beaty, JH. and Canale, ST. Campbell's Operative Orthopaedics. 13th ed. Philadelphia : Elsevier, 2016. p. 2852.
2. Rockwood CA, Green DP, Heckman JD, Bucholz RW. Rockwood and Green's Fractures in Adults. 8th ed. Philadelphia : Lippincott Wolters Kluwer, 2015. pp. 1983-90.
3. Kulambi V, Chaudhari K, Pethapara V. Anterior hip dislocation in young patient obturator (inferior) type: a rare case report. *Int J Res Orthop*. 2018 ;4(3):523-526.
4. Rahimi Shorin, H and Azizbeig Mohajer, M. Femoral Nerve Palsy Following Delayed Reduction of a Dislocated Hip in a 44- Year-old Man. *Iran Red Crescent Med J*. 2014 ;16(2):e12579.

Conclusion

Inferior hip dislocation with femoral nerve palsy is a rare type of hip dislocation. Diagnosis of the injury is clinically, with the position of the limb, and radiological investigations. It is important to examine neurologic function of the limb before reduction of a dislocation. In the cases of anterior hip dislocation with femoral nerve injury, it was hoped that the nerve would return. However, due to the rare nature of this injury, it is not possible to make a definitive statement.

5. Frew N, Foster P, Maury A. Femoral nerve palsy following traumatic posterior dislocation. *Injury*. 2013;44(2):261-2.
6. Stein, DA, et al. Low-energy anterior hip dislocation in a dancer. *Am J Orthop (Belle Mead NJ)*. 2002 ; 31(10):591-4.
7. Notzli, HP, et al. Perfusion of the femoral head during surgical dislocation of the hip. Monitoring by laser Doppler flowmetry. *J Bone Joint Surg Br*. 2002 ;84(2):300-4.
8. Ismael, S, Vora, J and Thomas, P. Adult Traumatic Inferior Hip Dislocation: Rare Case Ended with Open Reduction. *J Orthop Case Rep*. 2017 ;7(1):101-104.