

Bipolar Dislocation of Left Shoulder and Left Elbow: (Luxatio Erecta+Posterior Dislocation of Elbow) (A Case Report)

Abstract

This is a report on simultaneous dislocation of the left shoulder and elbow resulting in a 16 years old boy. Bipolar dislocation of Luxatio Erecta and posterior dislocation of the elbow is extremely rare. After clinical examinations (attention to pain, swelling, and deformity of the shoulder and elbow joints and neurovascular examinations), the necessary radiography was performed for the patient at the level of his tolerance: AP of the shoulder and side imaging of the elbow. Closed reduction was carried out with emergency maneuvers, followed by physiotherapy. Good result was obtained in the 6 weeks follow-up the examination of the adjacent joints of a dislocated limb is an important issue and must be emphasized.

Keywords: Bipolar, Luxatio Erecta, Dislocation, Shoulder, Elbow

Received: 4.5 months before printing; Accepted: 20 days before printing

* Amir Salari, MD; **Amir Reza Farhoud, MD; ***Ahmadreza Nezamslami, MD

*Orthopaedic Surgeon, Orthopaedic Research center, Department of orthopaedic, Poursina Hospital, Guilan university of medical sciences, Rasht, Iran
**Orthopaedic Surgeon, Tehran university of medical science , Tehran, Iran.
***Resident of Orthopaedic, Tehran university of medical science , Tehran, Iran.

* Correspondence

Amir Salari, MD,
Email Address:
Dr.amirsalari58@yahoo.com

Introduction

Shoulder dislocations are among the most common types of articular dislocations. While anterior dislocation is the most common type of shoulder dislocation, some patients present with posterior or inferior shoulder dislocation⁽¹⁻³⁾, 95% of which occur due to traumatic events^(4, 5). The elbow is the second most commonly dislocated joint after the shoulder⁽⁶⁾, and more than 90% of elbow dislocations are posterolateral. In addition, all shoulder and elbow dislocations require closed reduction. Despite the high incidence rate of these types of dislocation, their concomitant occurrence is extremely rare and often due to a high and severe force. This bipolar dislocation has been pointed out in several studies, all of which showed the anterior dislocation of the shoulder. A primary mechanism for the vertical dislocation of the shoulder is the direct axial force and indirect excessive shoulder abduction. Moreover, the classical mechanism for elbow dislocation is a direct axial force along with supination and valgus force. The common axial force in these types of dislocation might be the reason for bipolar dislocation of these joints⁽⁷⁻¹⁰⁾. To the best of our knowledge, no such case has been reported in the literature. Therefore, we aimed to evaluate a case of bipolar dislocation of Luxatio Erecta (inferior dislocation of the shoulder) and posterolateral elbow.

Case Report

On May 17th, 2018, a 16-year-old male patient was transferred to the emergency department of Imam Shariati Hospital of Tehran, Iran after falling from a height of three meters and

landing with hands, which led to severe pain and deformity of the left shoulder and elbow. During the examination, the limb was in full abduction (hand up dislocation), and there were shoulder and elbow swelling and deformity. However, the sensory and nerve

examination and pulse in the left upper limb were normal. In addition, AP elbow and lateral shoulder radiography were not performed for the patient due to his severe pain. In the radiographs taken from the patient, the

inferior dislocation of the shoulder (Luxatio Erecta) (Figure 1) along with posterolateral dislocation of the elbow was observed.

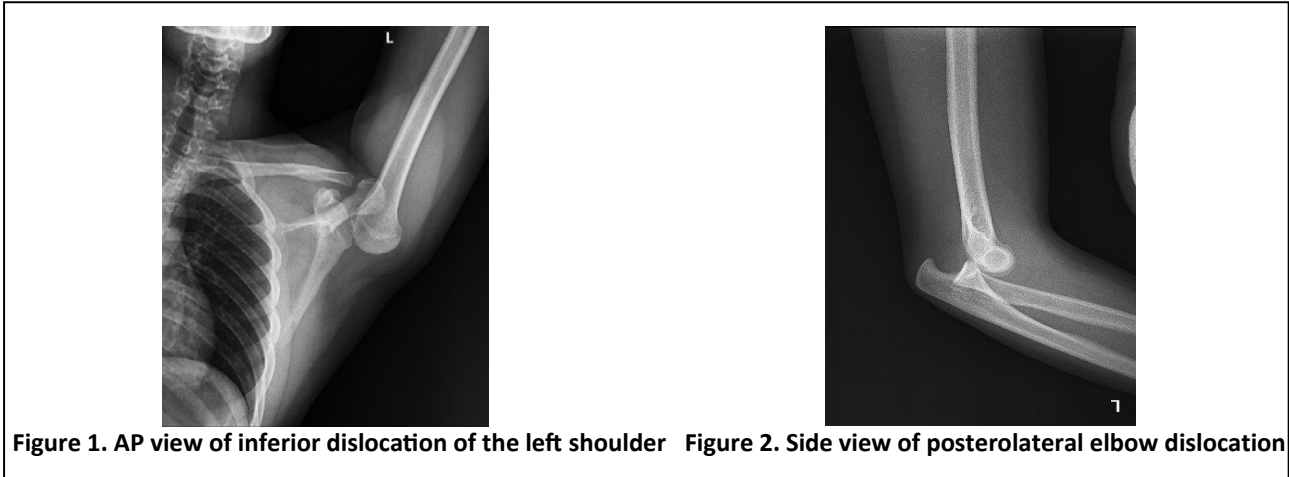


Figure 2 shows the profile view of posterolateral elbow dislocation. However, the AP view of the elbow was not obtained due to a lack of tolerance of patient in the position. After obtaining the informed consent from the patient and his companions and explaining the possible complications of shoulder and elbow dislocation, the patient was transferred to the orthopedic operating room. After the administration of anesthesia, closed reduction was performed, and the arm was placed in a

sling. One day after the operation, the patient was discharged in good general health and with normal neurovascular status. After three weeks of limb immobilization in a sling, the patient referred for another visit and underwent radiography for follow-up (figures 3 & 4). Three weeks after the reduction, swelling and pain in patient's hands completely disappeared and his shoulder and elbow had a normal range of motion.

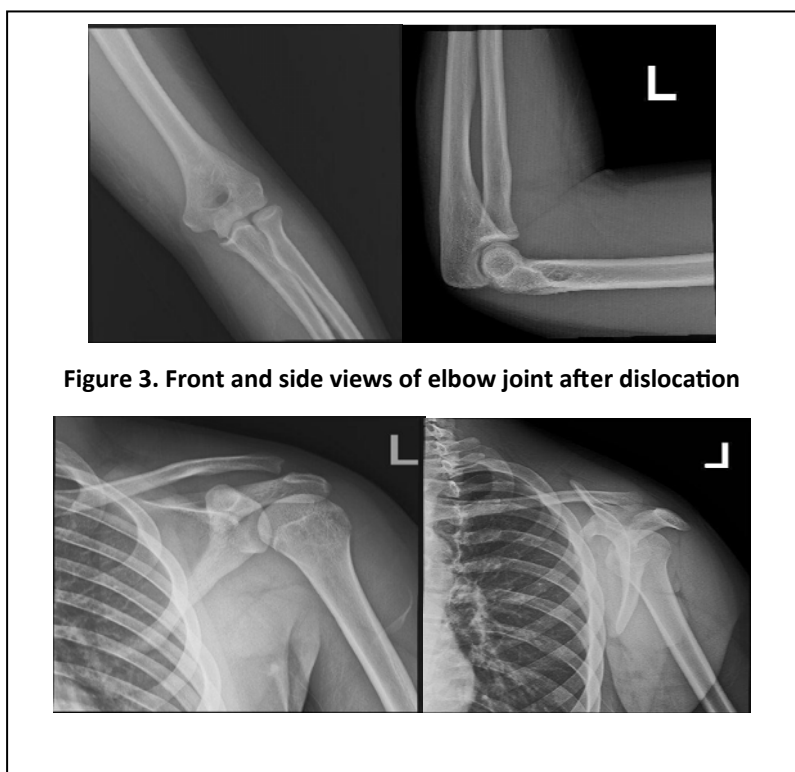


Figure 4. Front and side view of the shoulder after reduction

Six weeks after the reduction, the patient referred for follow-up, which showed no swelling, pain or reduction of range of motion. In addition, the patient was completely

satisfied with the surgery. Consent with the case report in the journal was obtained by the patient, and photographs were taken from the subject during treatment (Figure 5).

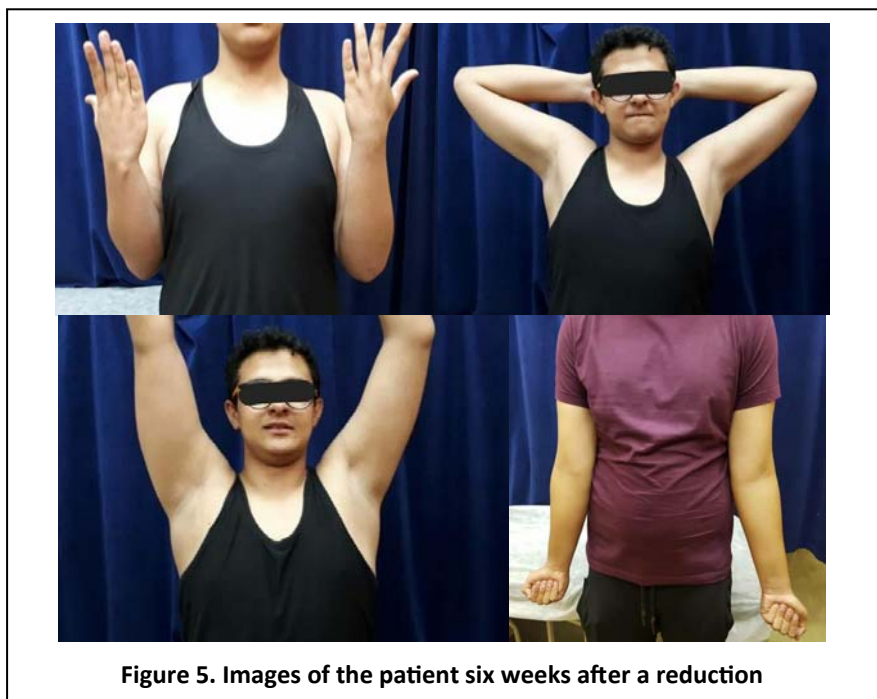

Figure 5. Images of the patient six weeks after a reduction

Discussion

Bipolar dislocation of Luxatio Erecta and posterolateral elbow is extremely rare, and no similar case has been observed in other studies. This type of dislocation occurs mainly due to severe trauma and require timely diagnosis and immediate intervention. In this regard, the neurovascular examination must be carried out before and after surgery. Reduction and immobilization are effective in the healing of this condition. The arm involved is placed in a sling to immobilize the limb. A primary mechanism for the vertical dislocation of the shoulder is the direct axial force and indirect excessive shoulder abduction. Moreover, the classical mechanism for elbow dislocation is a direct axial force along with supination and valgus force. The force applied in both dislocations is similar, which could justify the bipolar dislocation of the two joints. In a study by Ali et al. (1998), a 33-year-old overweight woman, was referred to the

hospital emergency department, was presented with pain in the left elbow and a clear deformity in favor of the problem, which was confirmed by imaging. While radiography showed a posterior elbow dislocation along with radial head fracture, the patient did not complain of shoulder pain. Nevertheless, posterior dislocation in the left shoulder was observed in the radiography. Both of these dislocations were reduced after general anesthesia⁽⁸⁾. In another case report, Songahir et al. (2018) described a 43-year-old male with a fracture and dislocation of the right shoulder and elbow. Examinations revealed anteromedial shoulder dislocation and posterolateral elbow dislocation. Reduction and physiotherapy were carried out for the patient, associated with the patient's recovery⁽¹¹⁾. Two out of three patients presented were obese^(8,12), and our patient had an inferior shoulder dislocation along with simultaneous posterolateral elbow dislocation without any fracture. However, this condition

was associated with a fracture in other studies. One of the major drawbacks of this study was the lack of ability to place the patient in a proper position for radiography.

Conclusion

Despite the rare incidence of this type of dislocation, it occurs by the direct impact of

severe trauma. In this regard, the timely closed reduction must be carried out applying the appropriate techniques. In addition, immobility after surgery significantly contributes to the recovery of patients and the return of organ function.

Conflict of Interest: The authors declare no conflict of interest, financial or otherwise.

Acknowledgements: Declared none.

References

1. Matsen FA III, Thomas SC, Rockwood CA Jr. Anterior glenohumeral instability. Rockwood CA Jr, Matsen FA III, editors: The Shoulder. Vol 1. Philadelphia, Pa; WB Saunders Co; 1990. p. 526-622.
2. Schenk TJ, Brems JJ. Multidirectional instability of the shoulder: Pathophysiology, diagnosis, and management. *J Am Acad Orthop Surg.* 1998;6:65-72.
3. Cofield RH, Kavanagh BF, Frassica FJ. Anterior shoulder instability. *Instr Course Lect.* 1985;34:210-27.
4. Dodson CC, Cordasco FA. Anterior glenohumeral joint dislocations. *Orthop Clin North Am.* 2008;39:507-18, vii.
5. Burkhead WZ, Jr., Rockwood CA, Jr. Treatment of instability of the shoulder with an exercise program. *J Bone Joint Surg Am.* 1992;74:890-6.
6. Martin BD, Johansen JA, Edwards SG. Complications related to simple dislocations of the elbow. *Hand Clin.* 2008;24:9-25.
7. Imerci A, Kumbaraci M, İncesu M, Savran A, Karapinar L. Ipsilateral simultaneous shoulder and elbow dislocation: A case report. *Tr J Emerg Med.* 2011;11(2):72-5.
8. Ali FM, Krishnan S, Farhan MJ. A case of ipsilateral shoulder and elbow dislocation: an easily missed injury. *J Accid Emerg Med.* 1998;15:198.
9. Essoh JS, Kodo M, Traoré A, Lambin Y. Ipsilateral dislocation of the shoulder and elbow: A case report. *Nigerian journal of surgical research.* 2005;7(3-4):319-20.
10. Inan U, Cevik AA, Omeroglu H. Open humerus shaft fracture with ipsilateral anterior shoulder fracture-dislocation and posterior elbow dislocation: a case report. *J Trauma.* 2008;64:1383-6.
11. Songahir Christophe DA, Alexandre K, Sayouba T, Mamoudou S, Hamado K, Anatole Jean Innocent O, et al. Bipolar dislocation of the arm (shoulder and elbow): About one case in an African Teaching Hospital. *Open Orthop J.* 2018;12:147-52.
12. Khan MR, Mirdad TM. Ipsilateral dislocation of the shoulder and elbow. *Saudi Med J.* 2001;22:1019-21.